

Unidad de Anatomía Veterinaria UST. Santiago

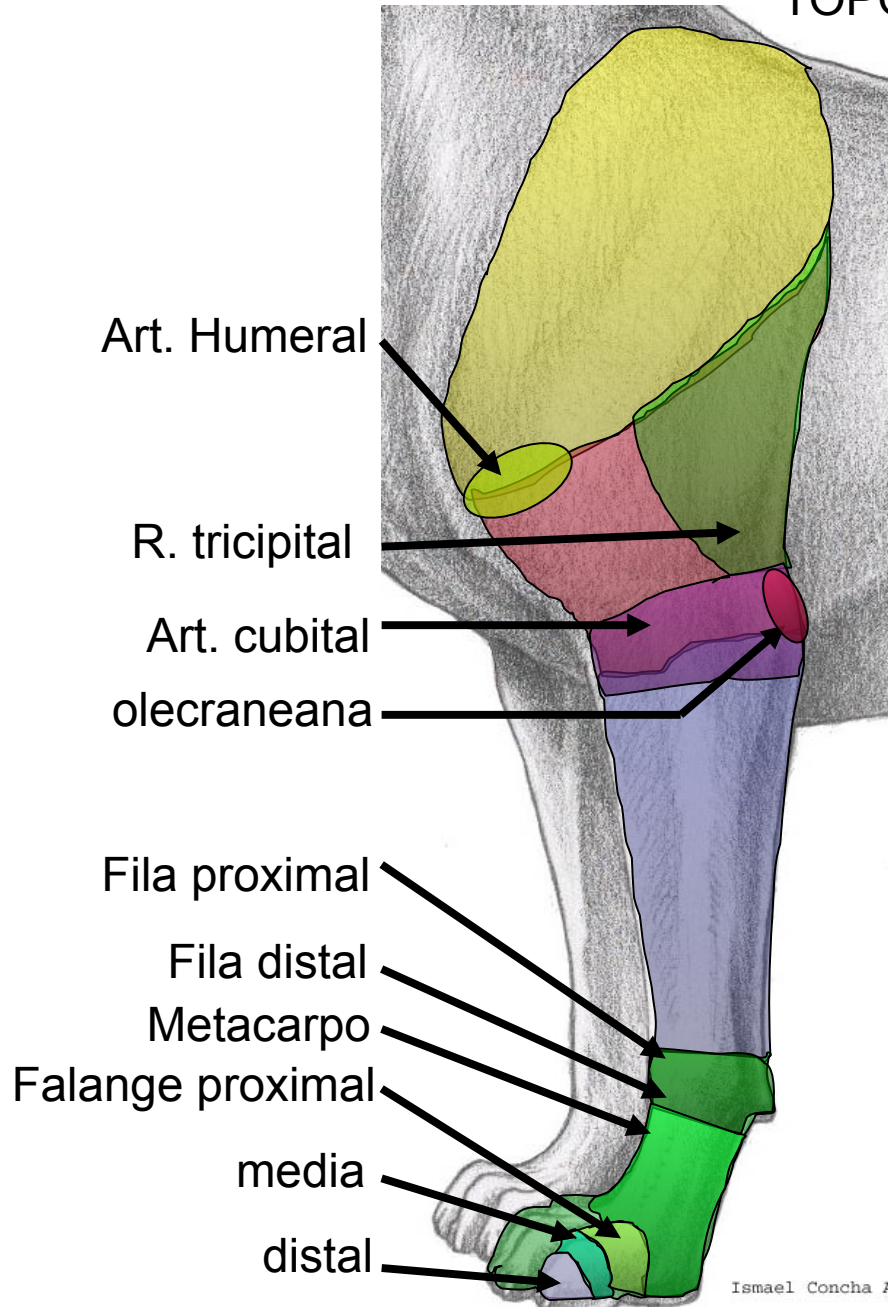


Osteología y artrología de miembros de canino

Dr. Ismael Concha A.

www.anato.cl

TOPOGRAFIA

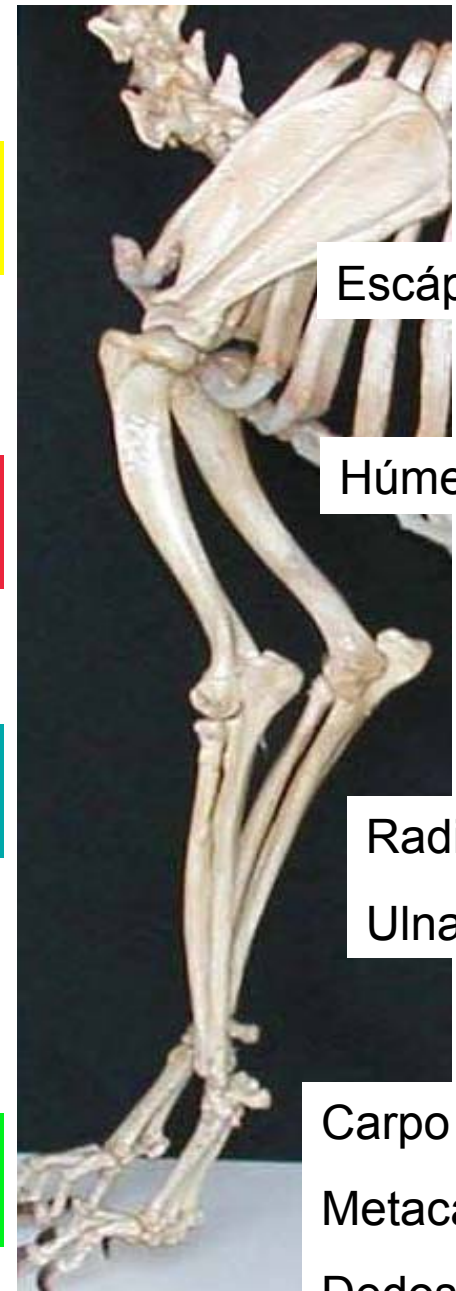


Cíngulo Mb torácico

Región braquial

Región antebraquial

Región de la mano



Escápula

Húmero

Radio

Ulna

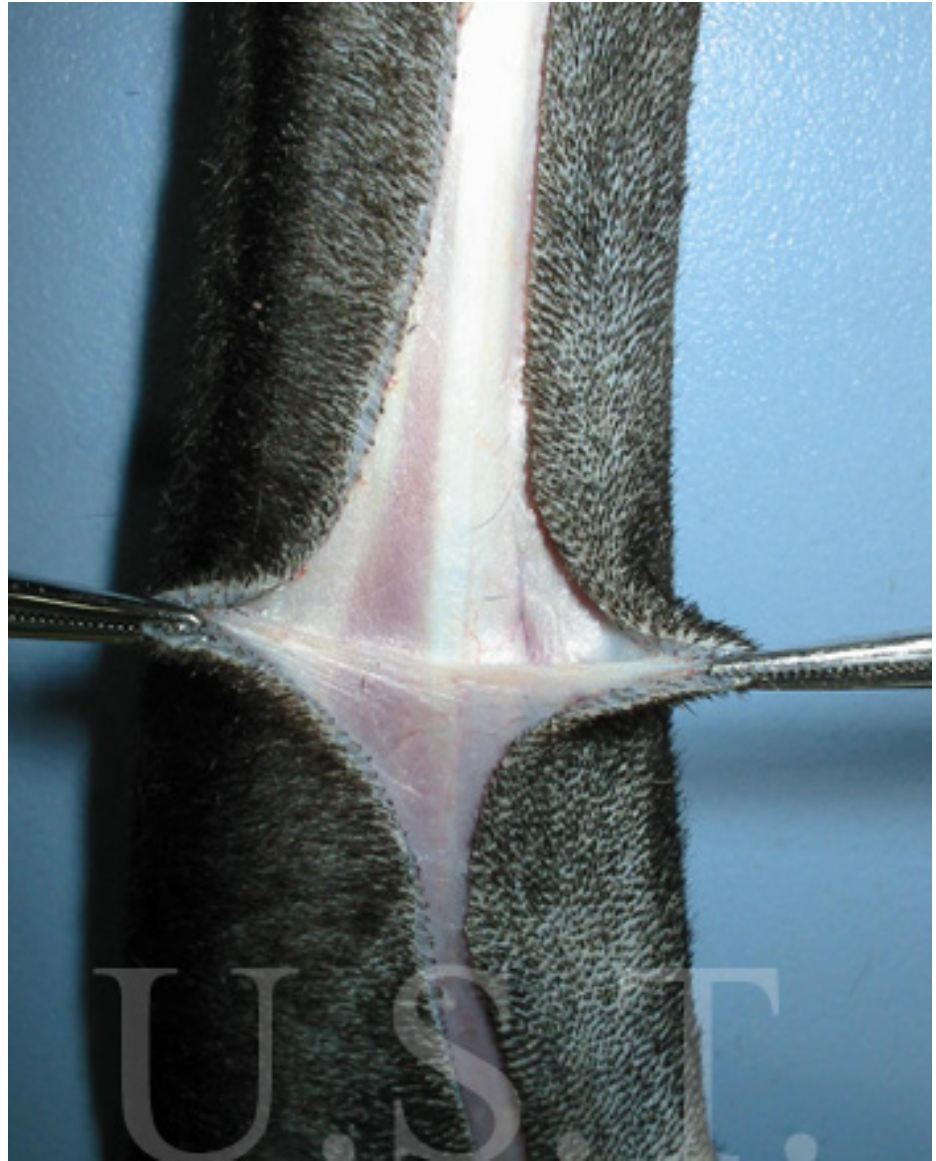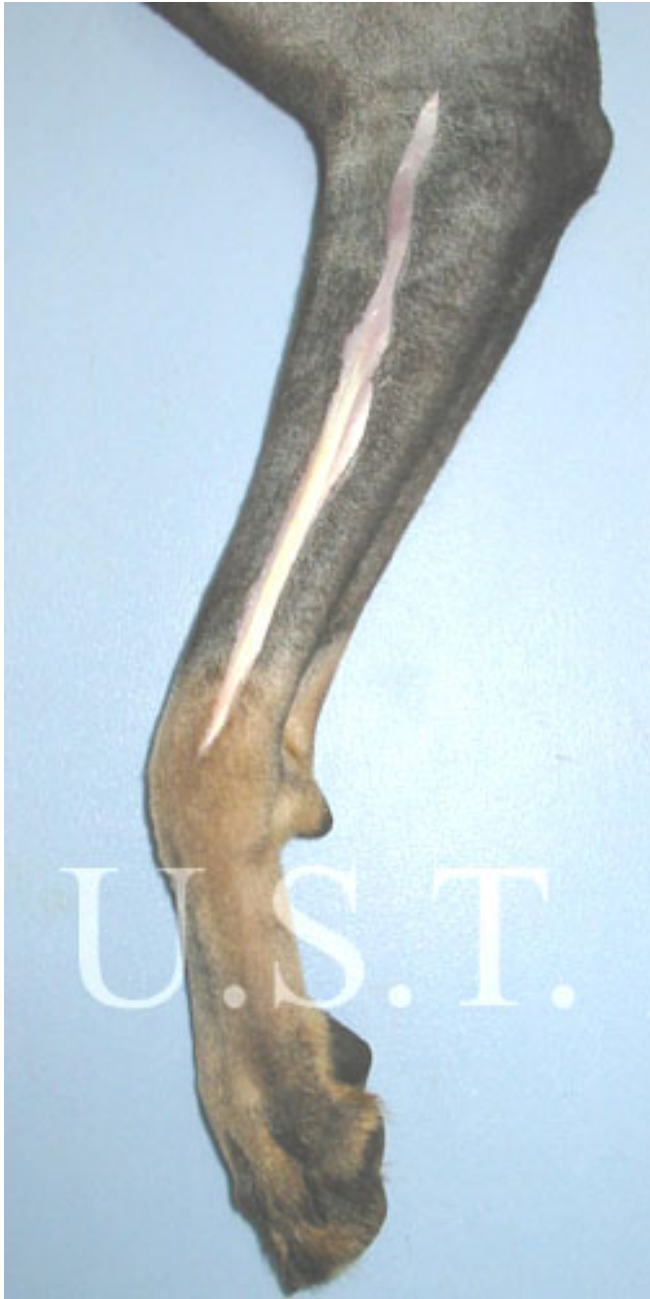Carpo

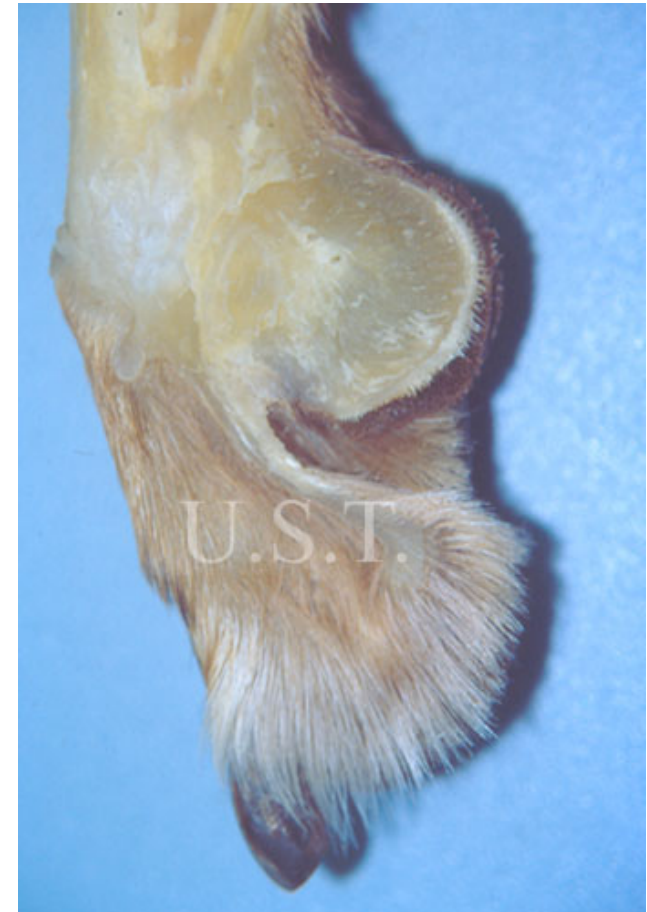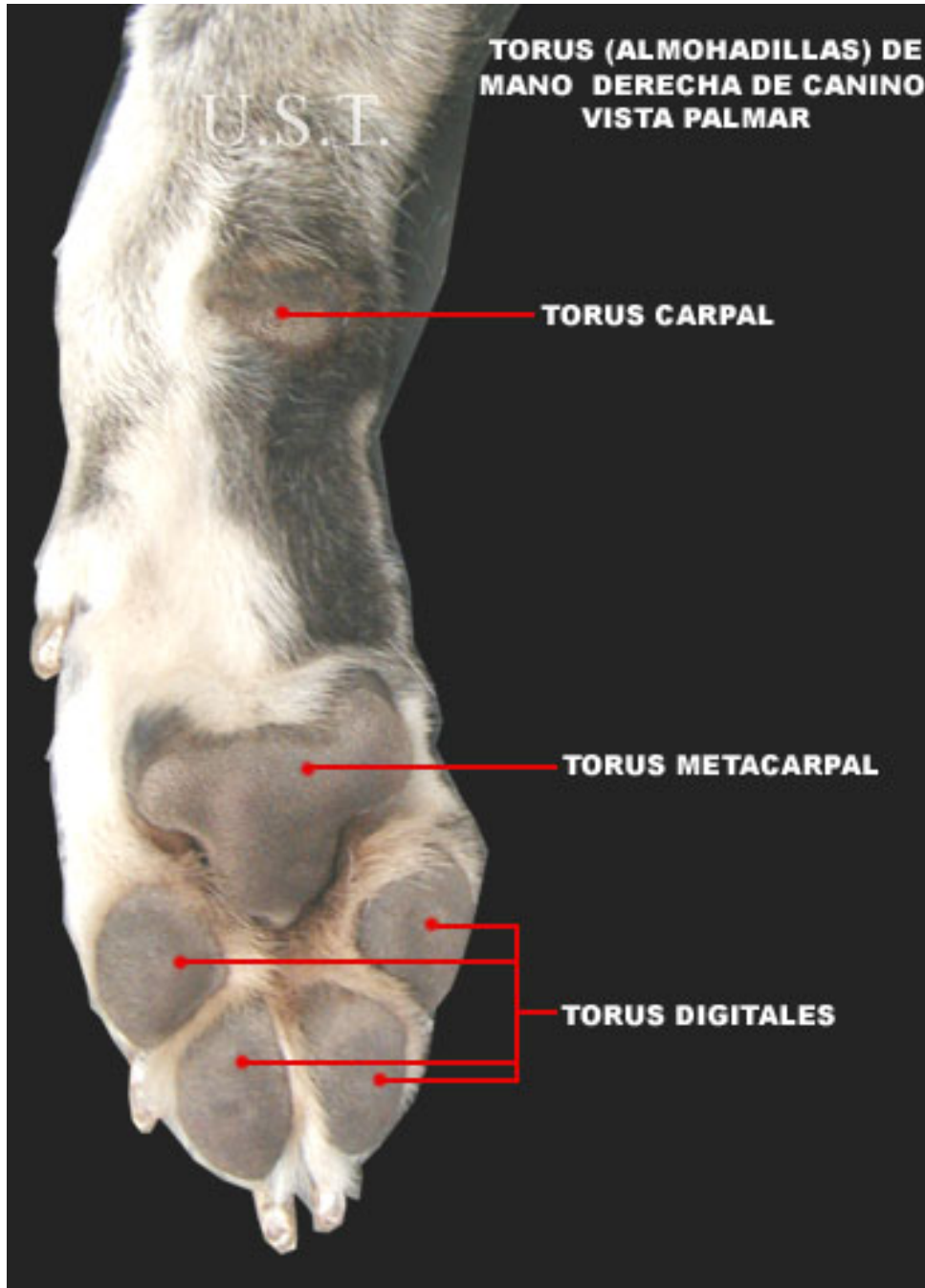
Metacarpo

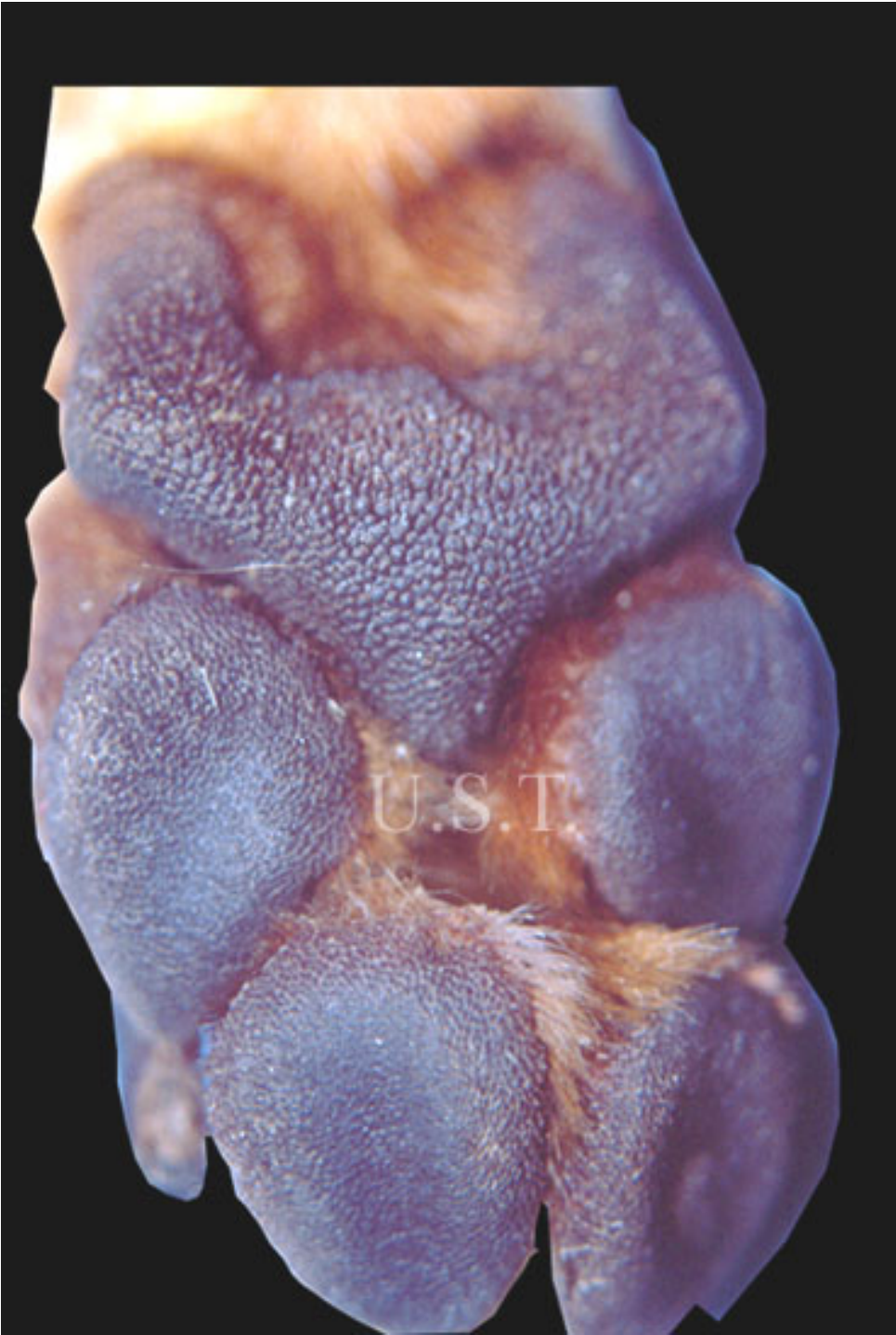Dedos

Tegumento

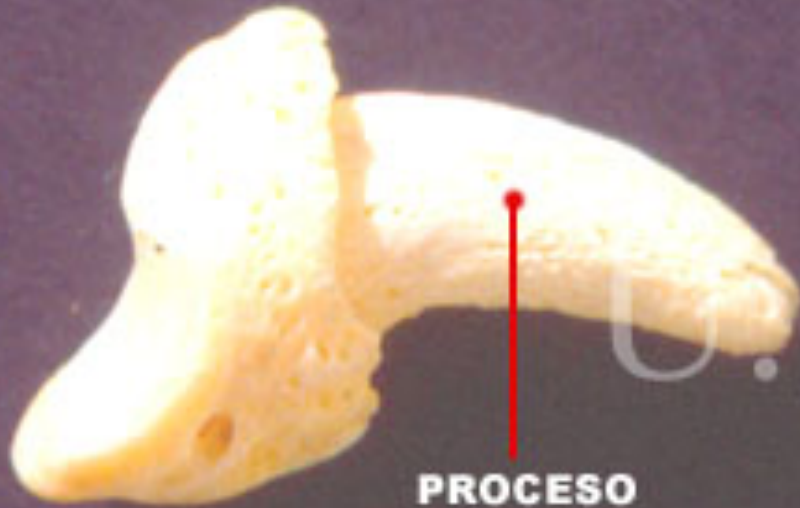- Pelos de cubierta
- Tela subcutánea delgada
- Torus: (Cojinetes o almohadillas)
 - carpal, metacarpal y digitales
- Unguícula: (Garra)
 - porciones laterales y suela





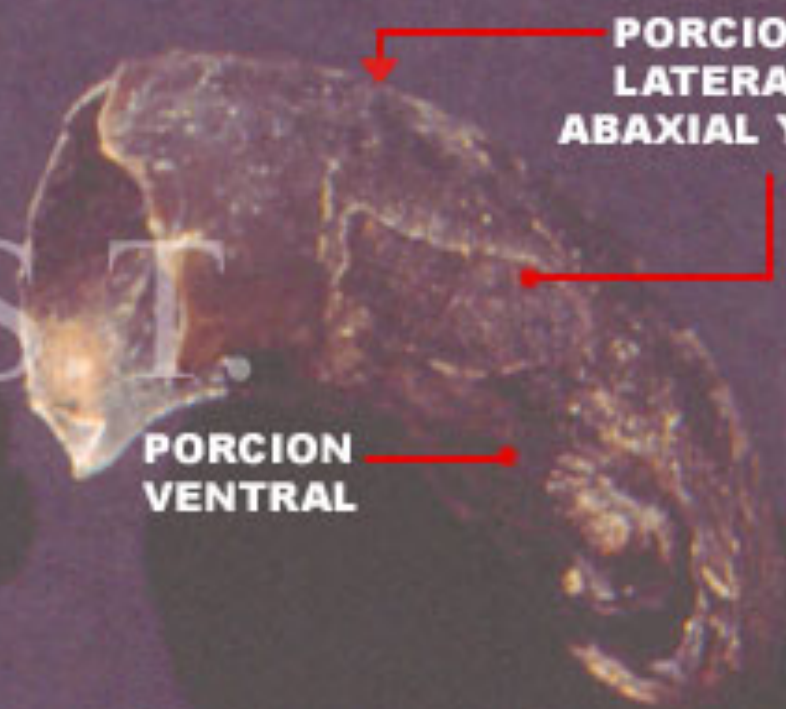


**TERCERA FALANGE
DE CANINO**



**PROCESO
UNGUICULAR**

**UNGUICULA
(UÑA O GARRA)**

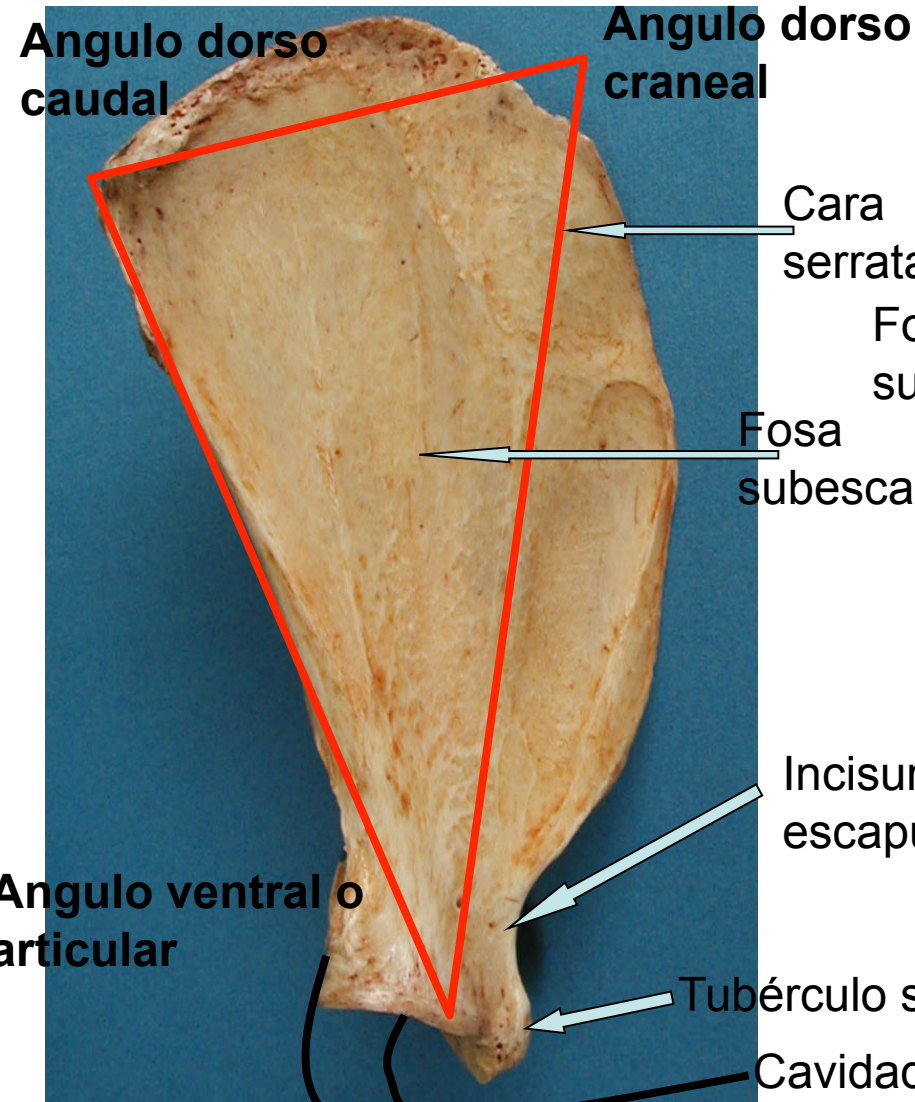


**PORCIONES
LATERALES
ABAXIAL Y AXIAL**

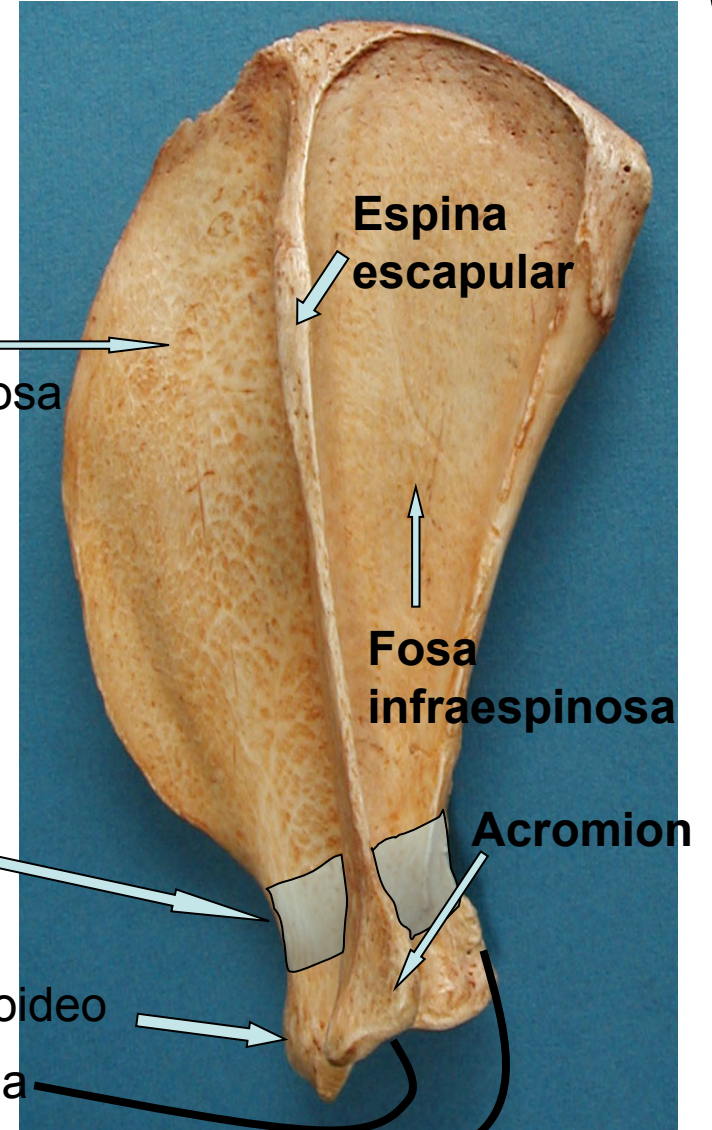
**PORCION
VENTRAL**

ESCAPULA

VISTA MEDIAL

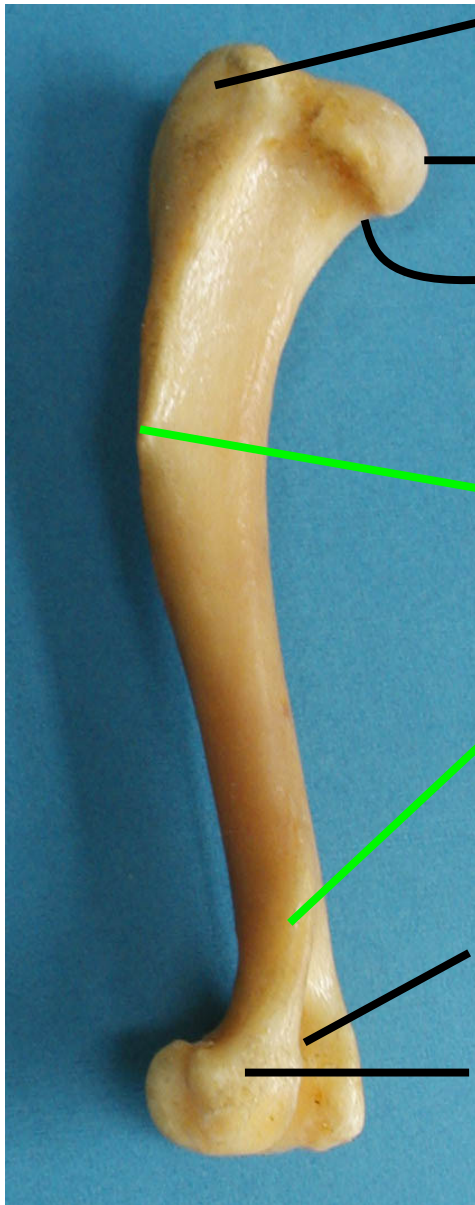


VISTA LATERAL

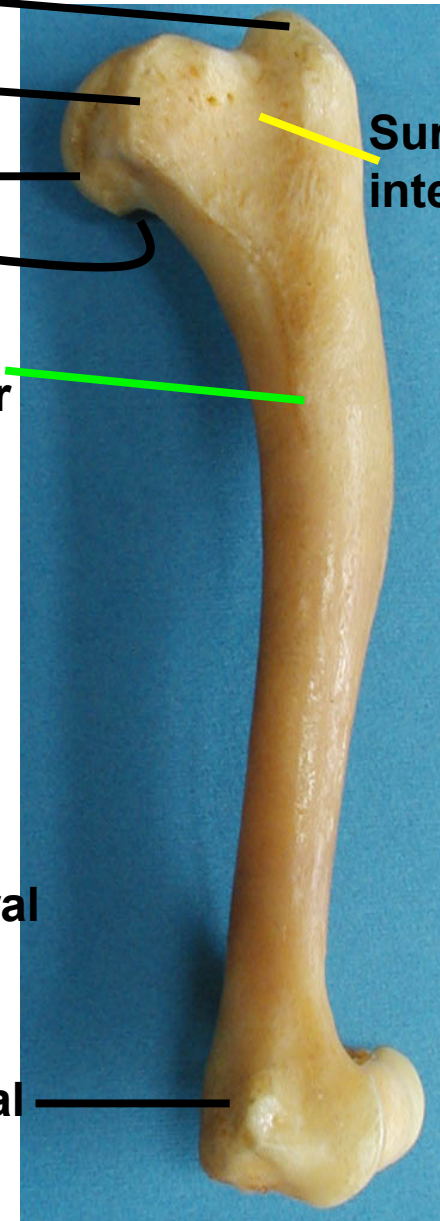


HUMERO

VISTA LATERAL



VISTA MEDIAL



Tubérculo mayor

Tubérculo menor

Cabeza

Cuello

Tuberosidad
redondo mayor

Tuberosidad
deltoidea

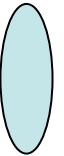
Cresta supracondilar
lateral

Cóndilo humeral

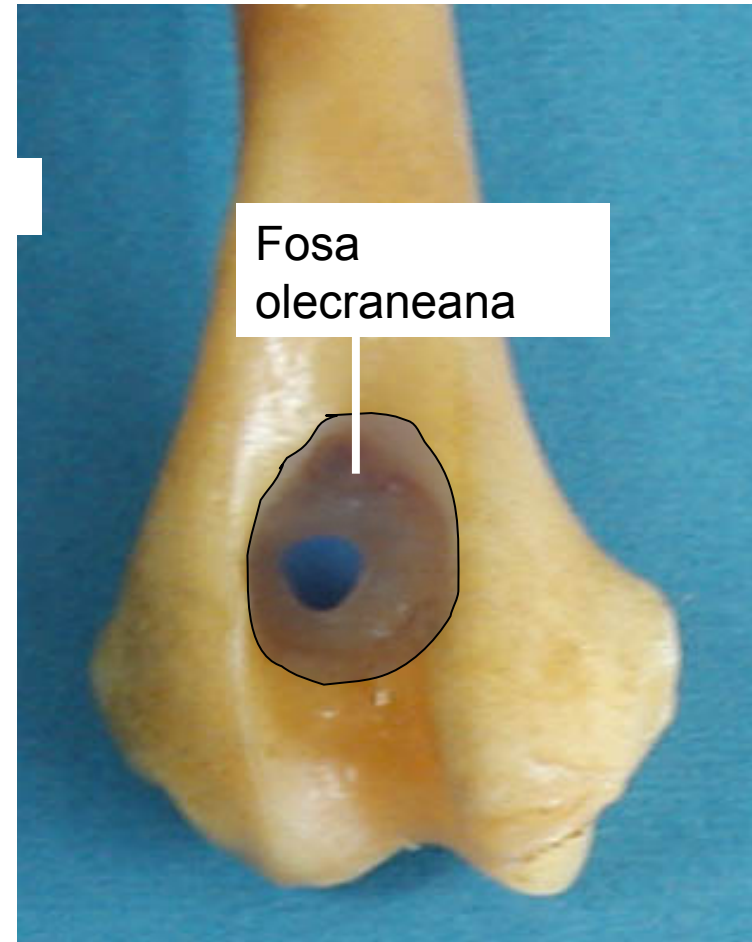
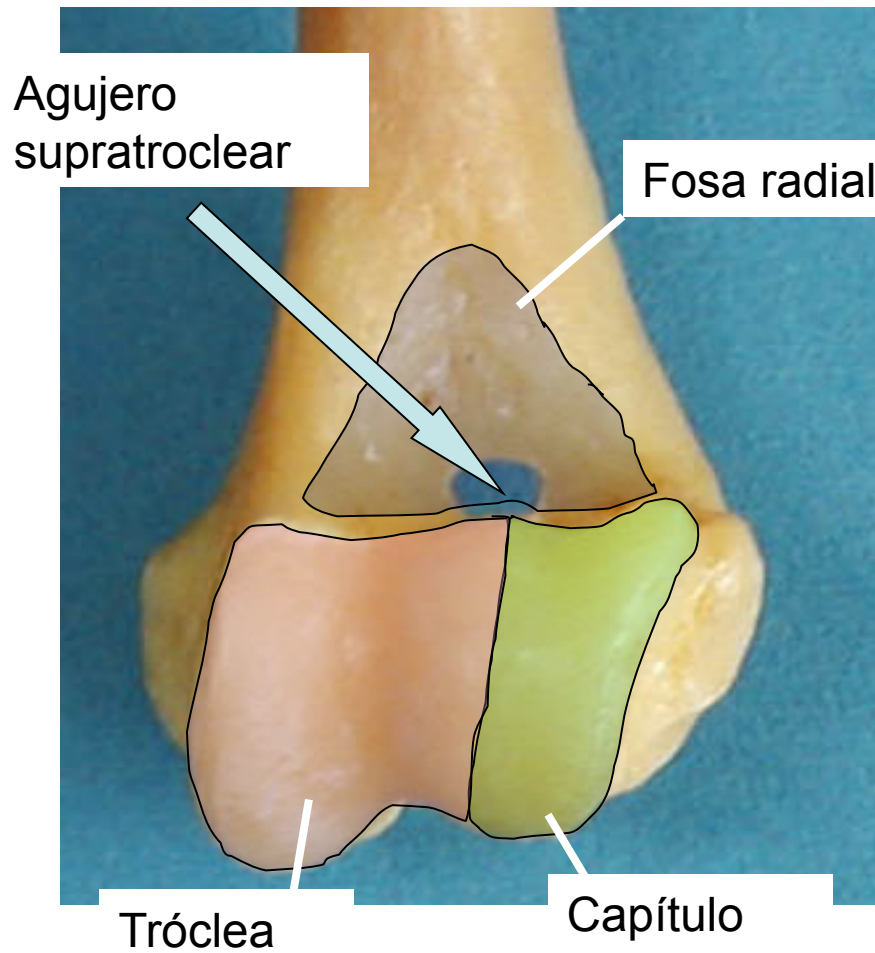
Fosa olecraneana

Epicóndilo lateral y medial

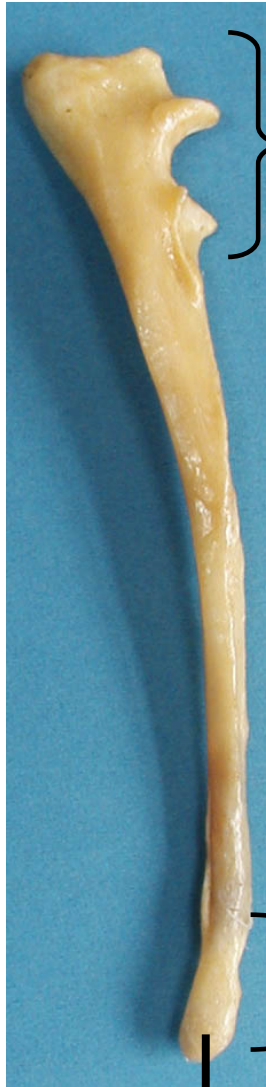Surco
intertubercular



Ep.distal humeral- C6ndilo humeral



Ulna



Olécranon

Cabeza

Proceso estilóideo

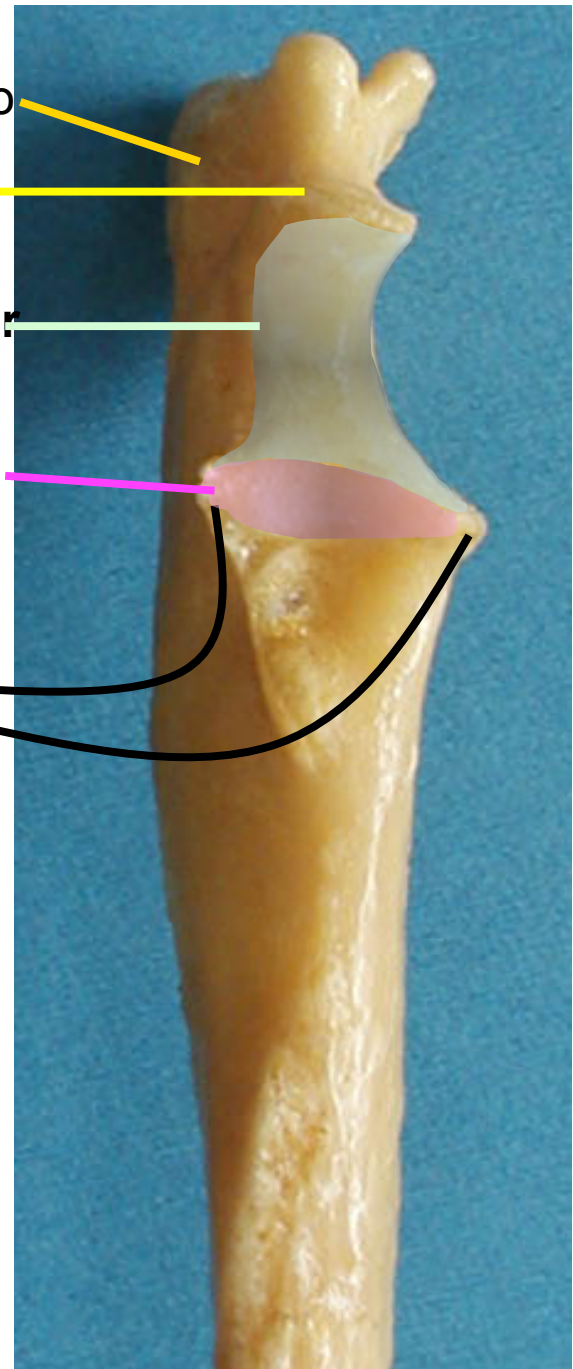
Tubérculo olecraneano

Proceso anconeo

Incisura troclear

Incisura radial

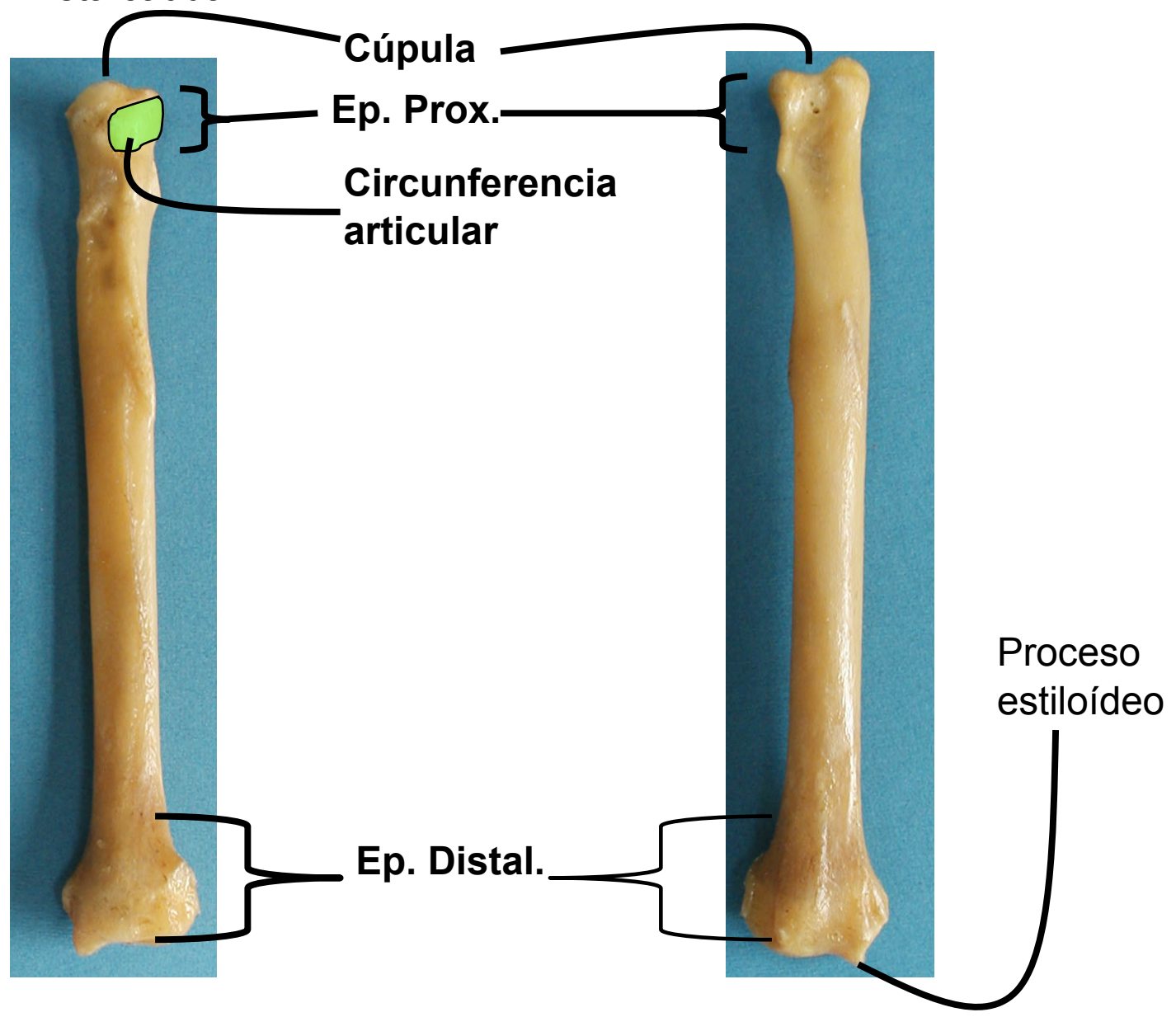
Procesos coronoideos
lateral y medial



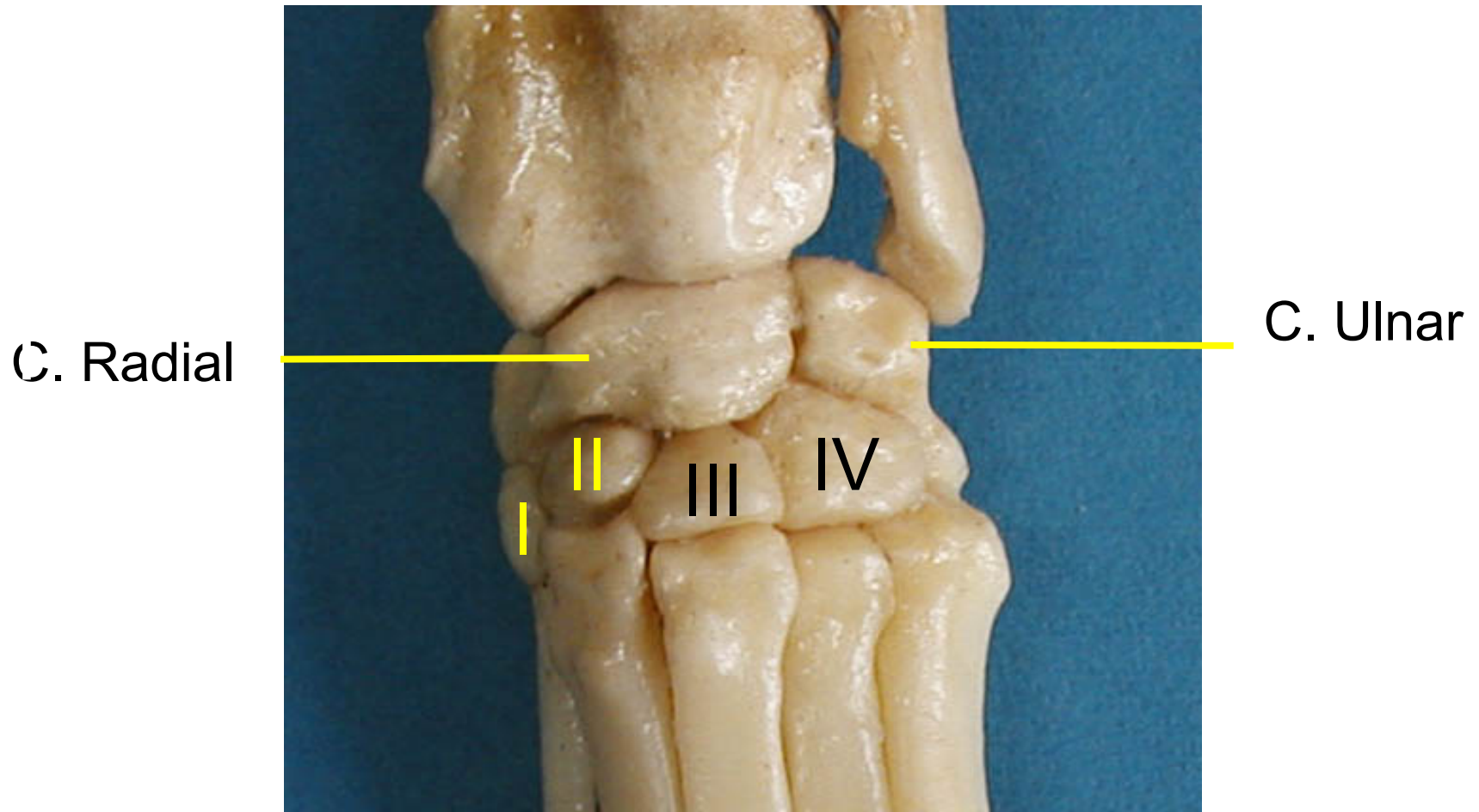
Radio

Vista caudal

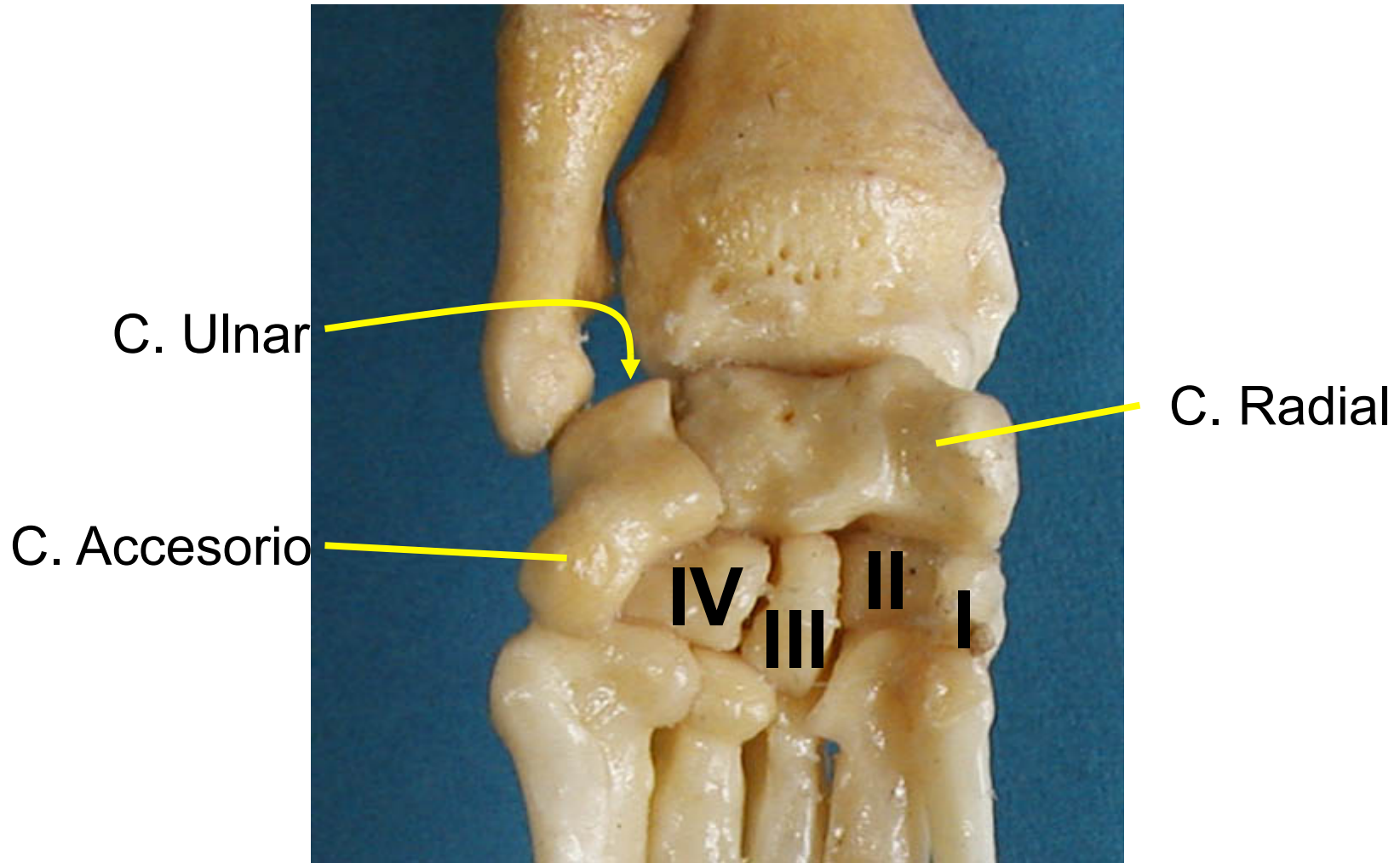
Vista craneal



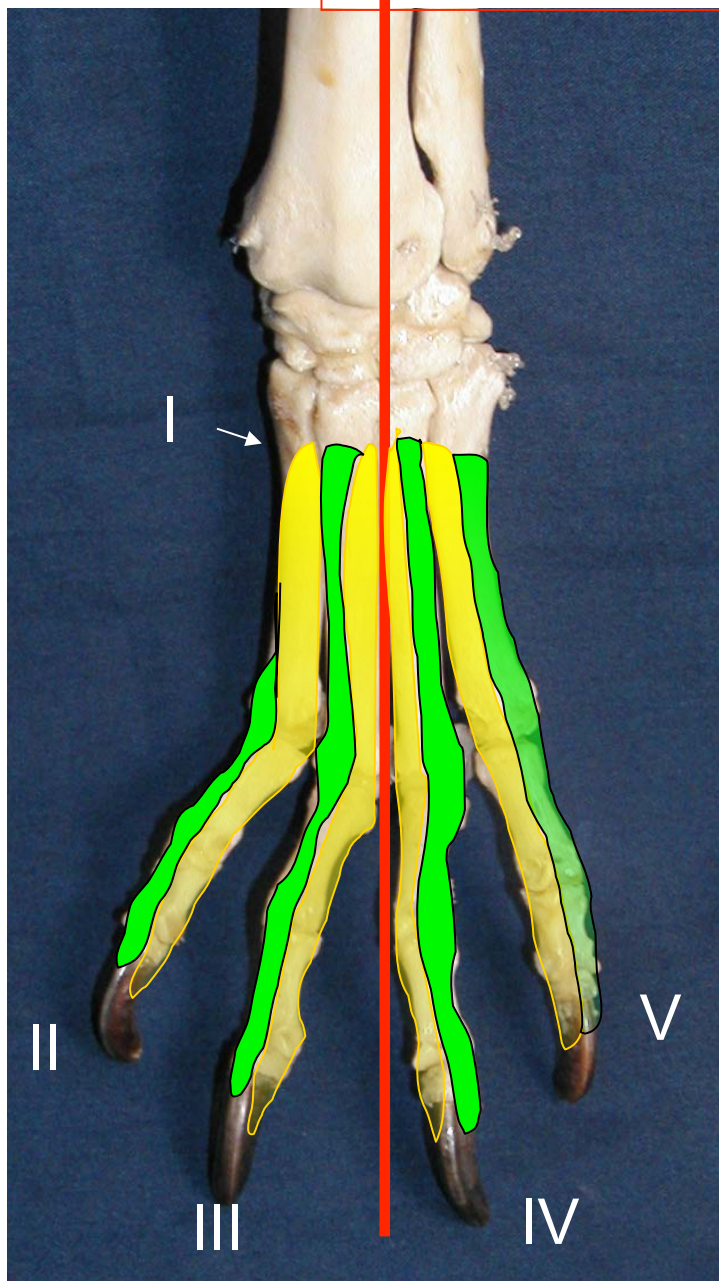
Mano - carpo



Mano - carpo



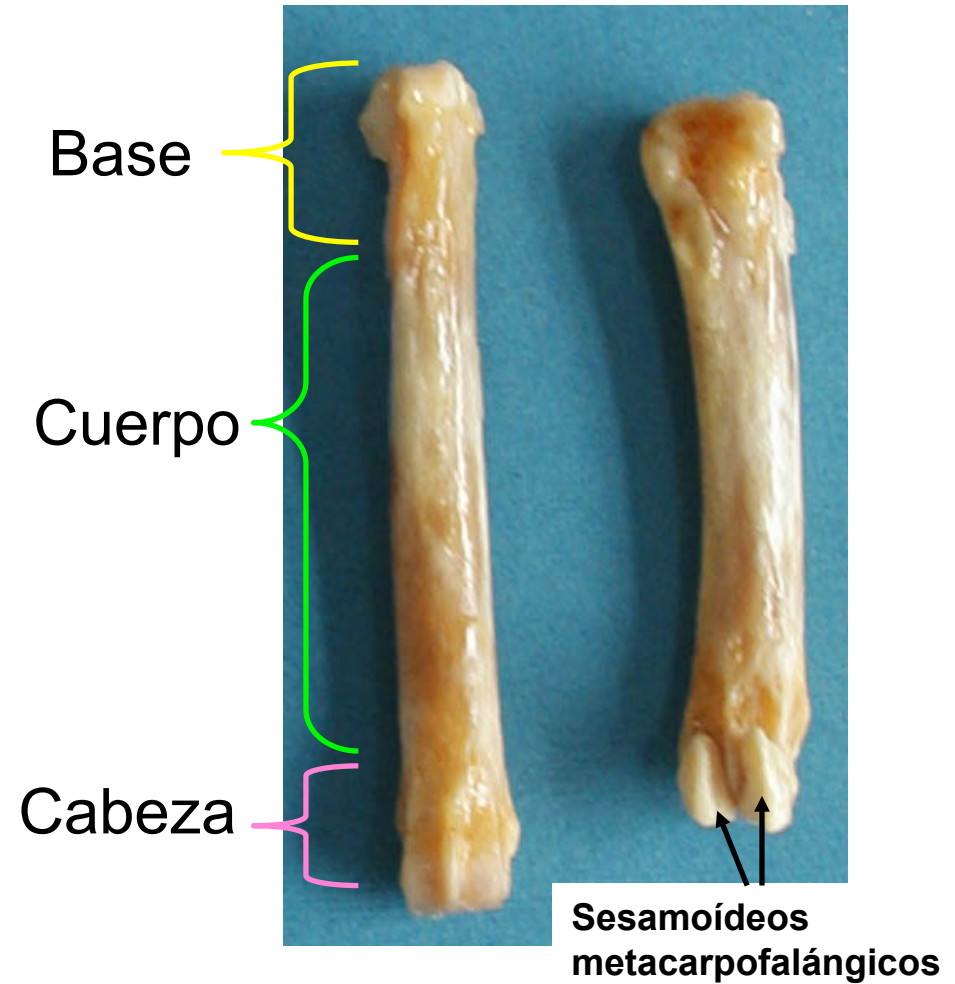
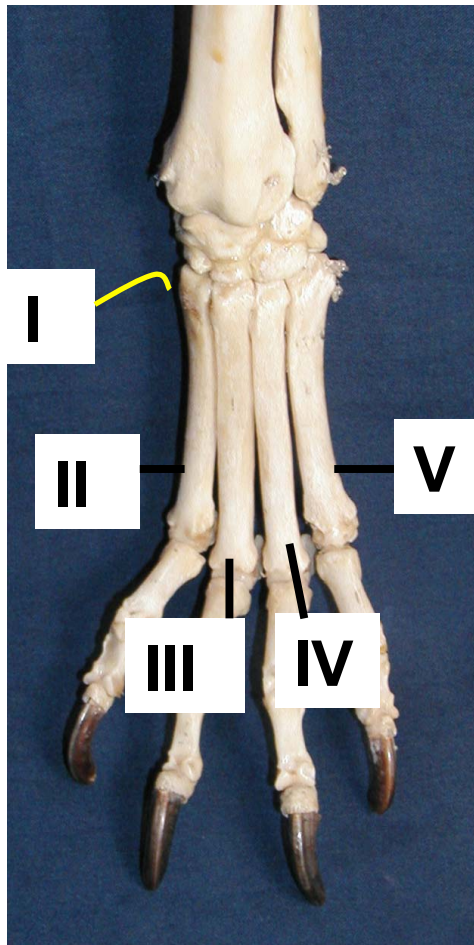
AXIS



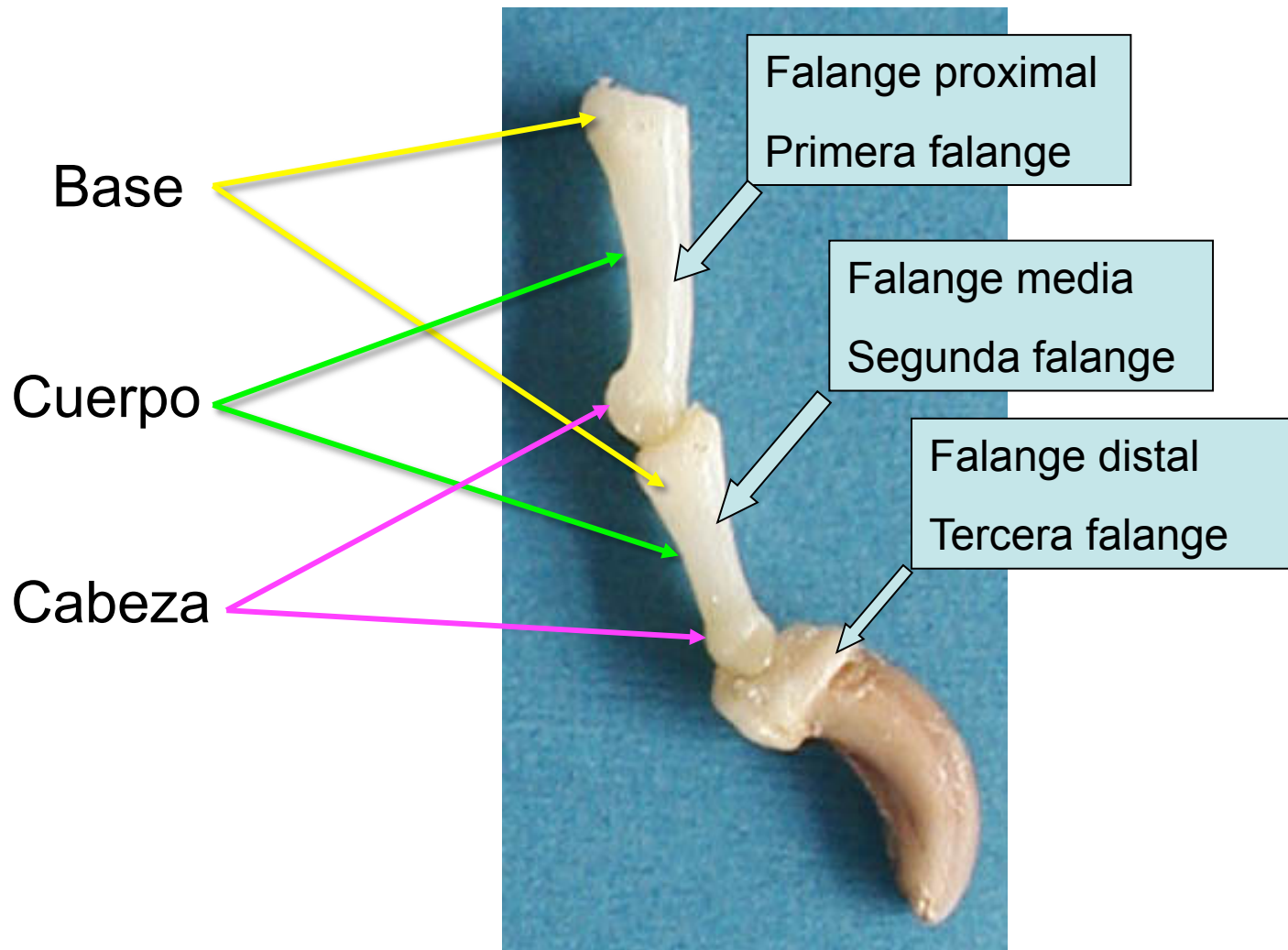
AXIAL

ABAXIAL

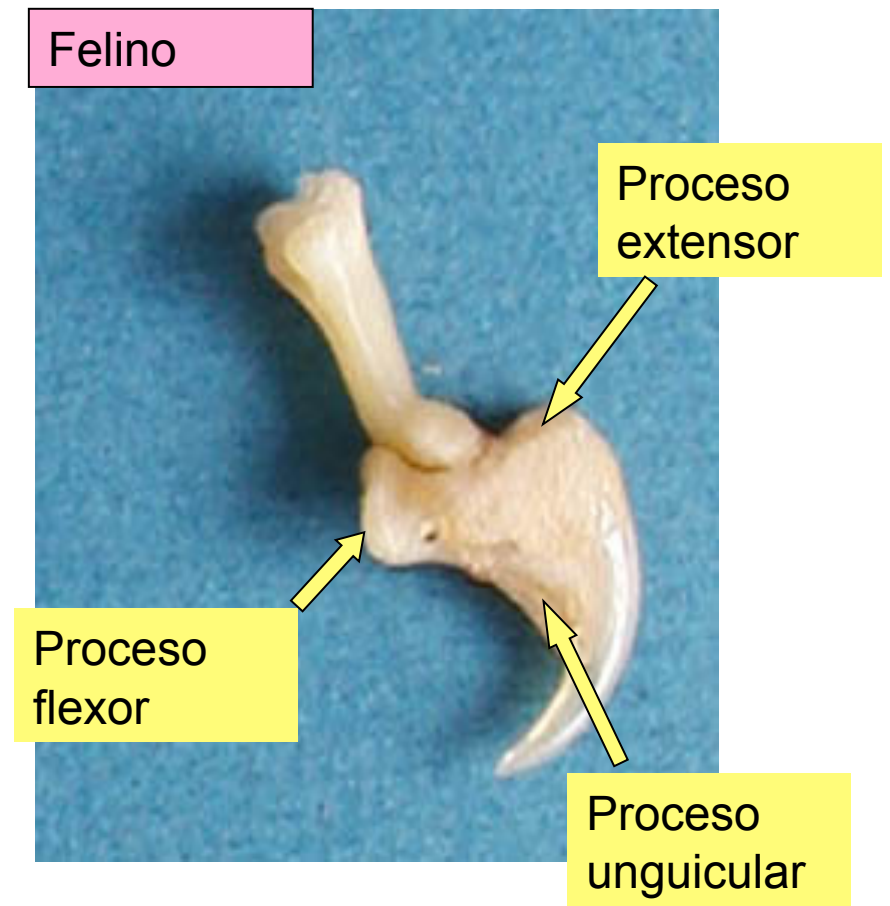
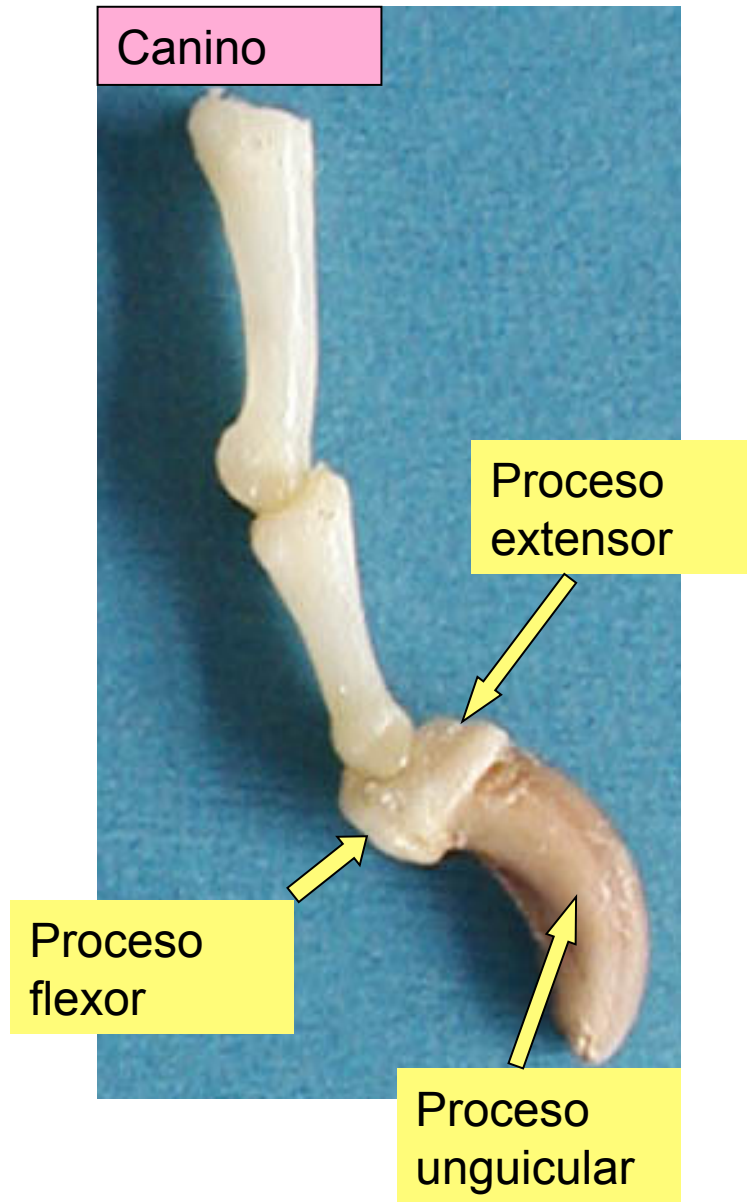
Mano - metacarpo



Mano - dedos



Mano - dedos



humano

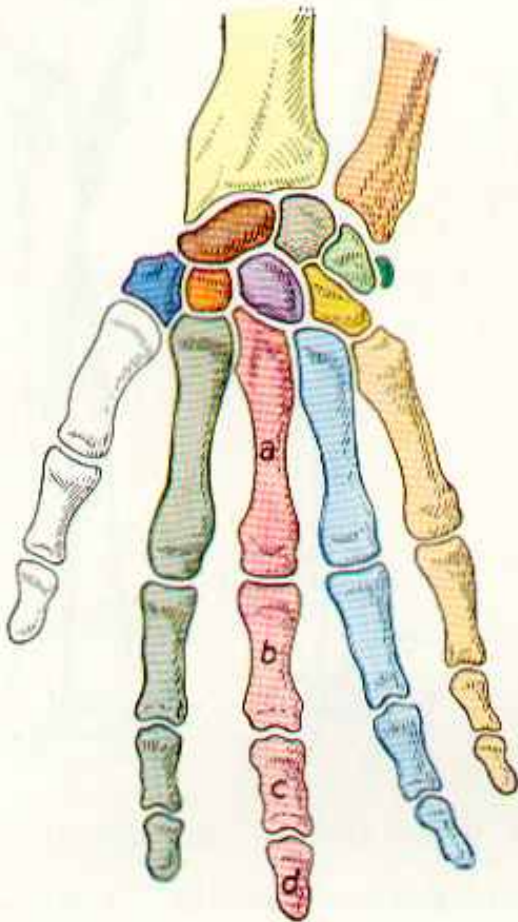


Abb. 116 (Mensch)

canino

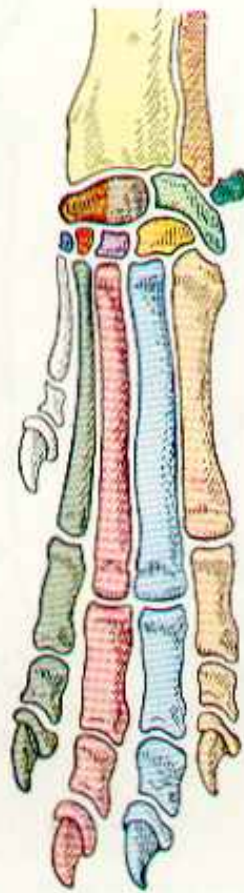


Abb. 117 (Hund)

porcino

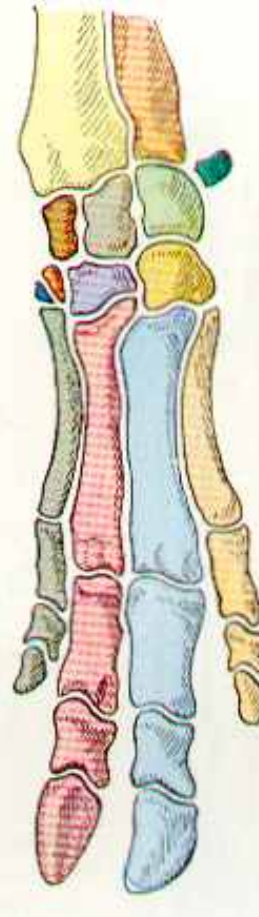


Abb. 118 (Schwein)

bovino

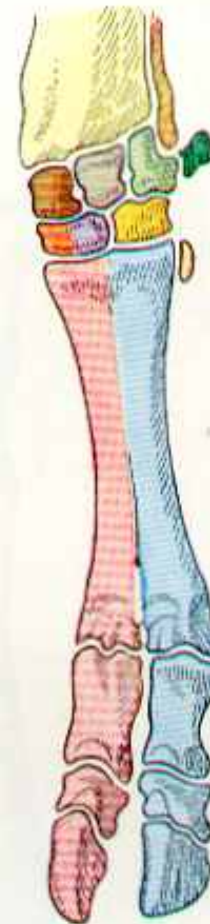


Abb. 119 (Rind)

equino

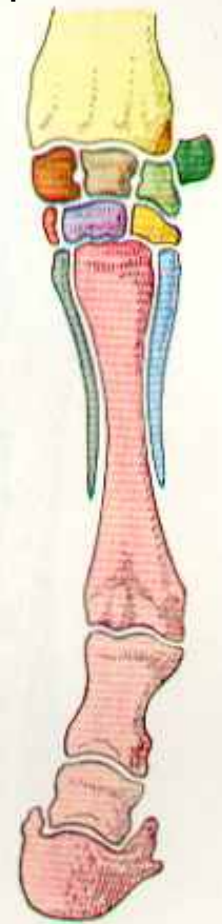
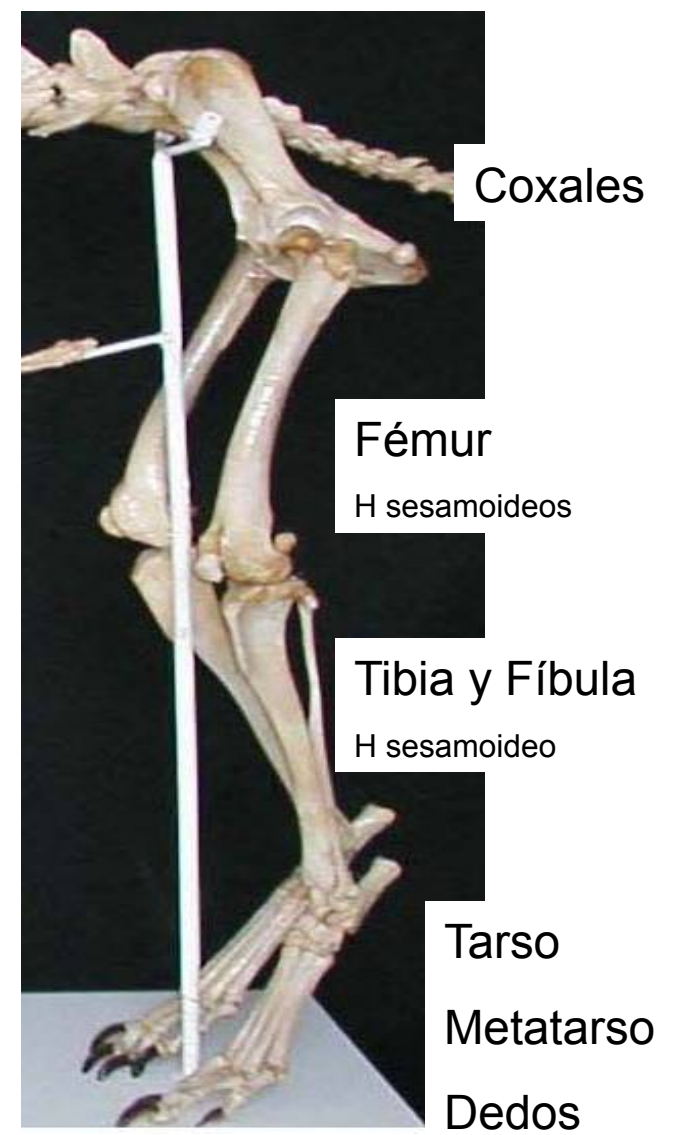
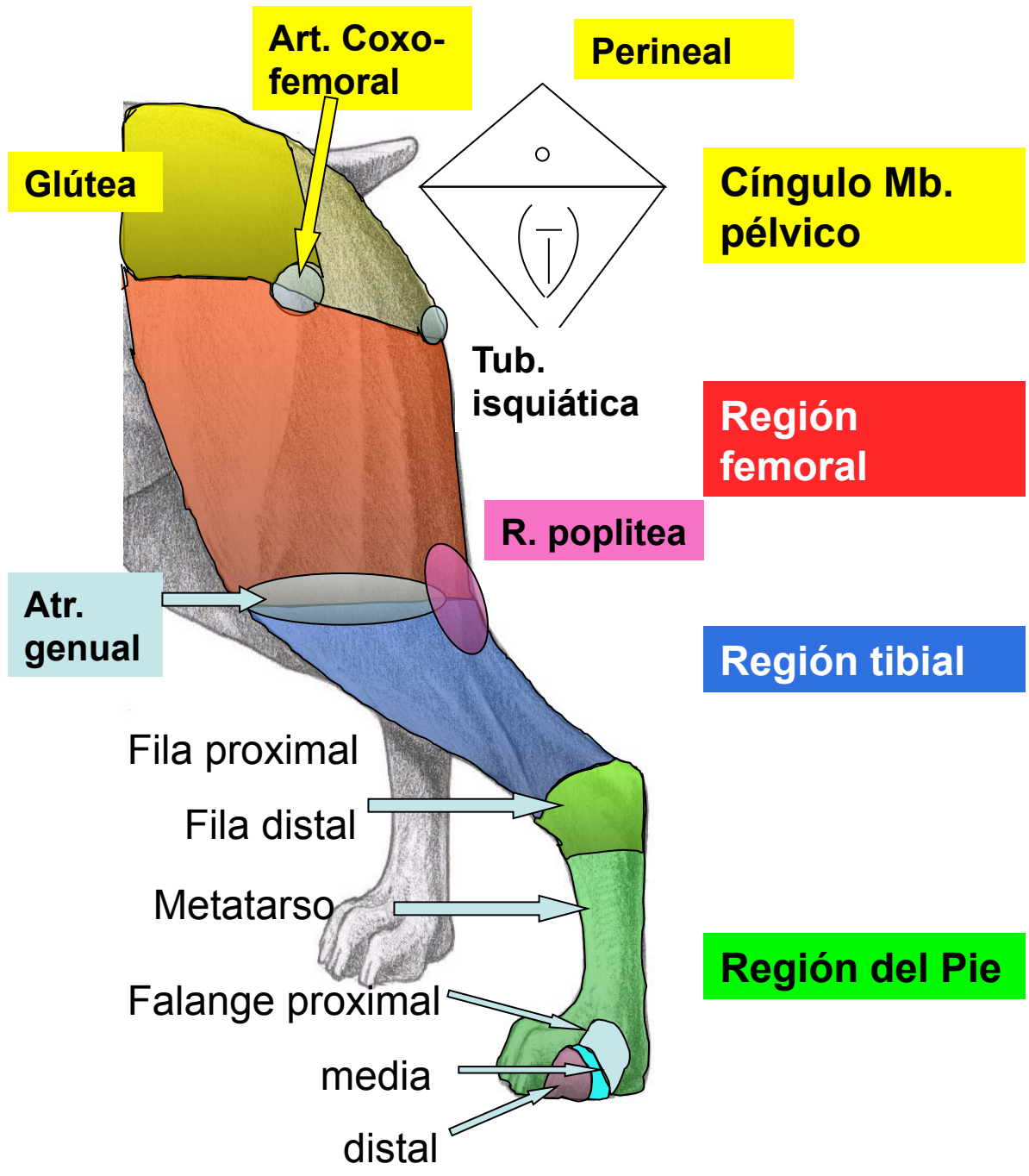


Abb. 120 (Pferd)

Cíngulo y Miembro Pélvico

- Topografía
- Tegumento
- Osteología
- Artrología



U.S.T.

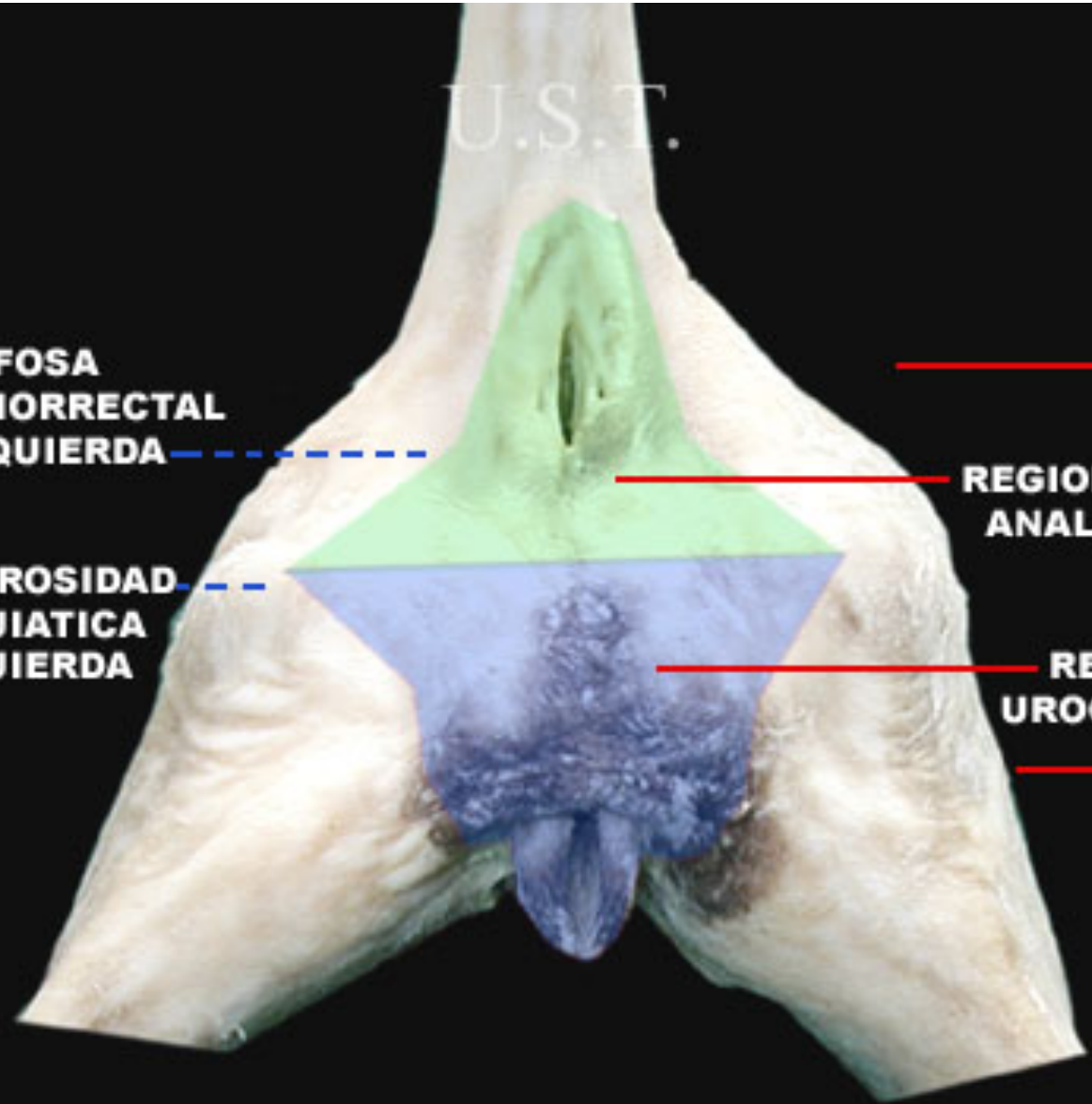
FOSA
ISQUIORRECTAL
IZQUIERDA

TUBEROSIDAD
ISQUIATICA
IZQUIERDA

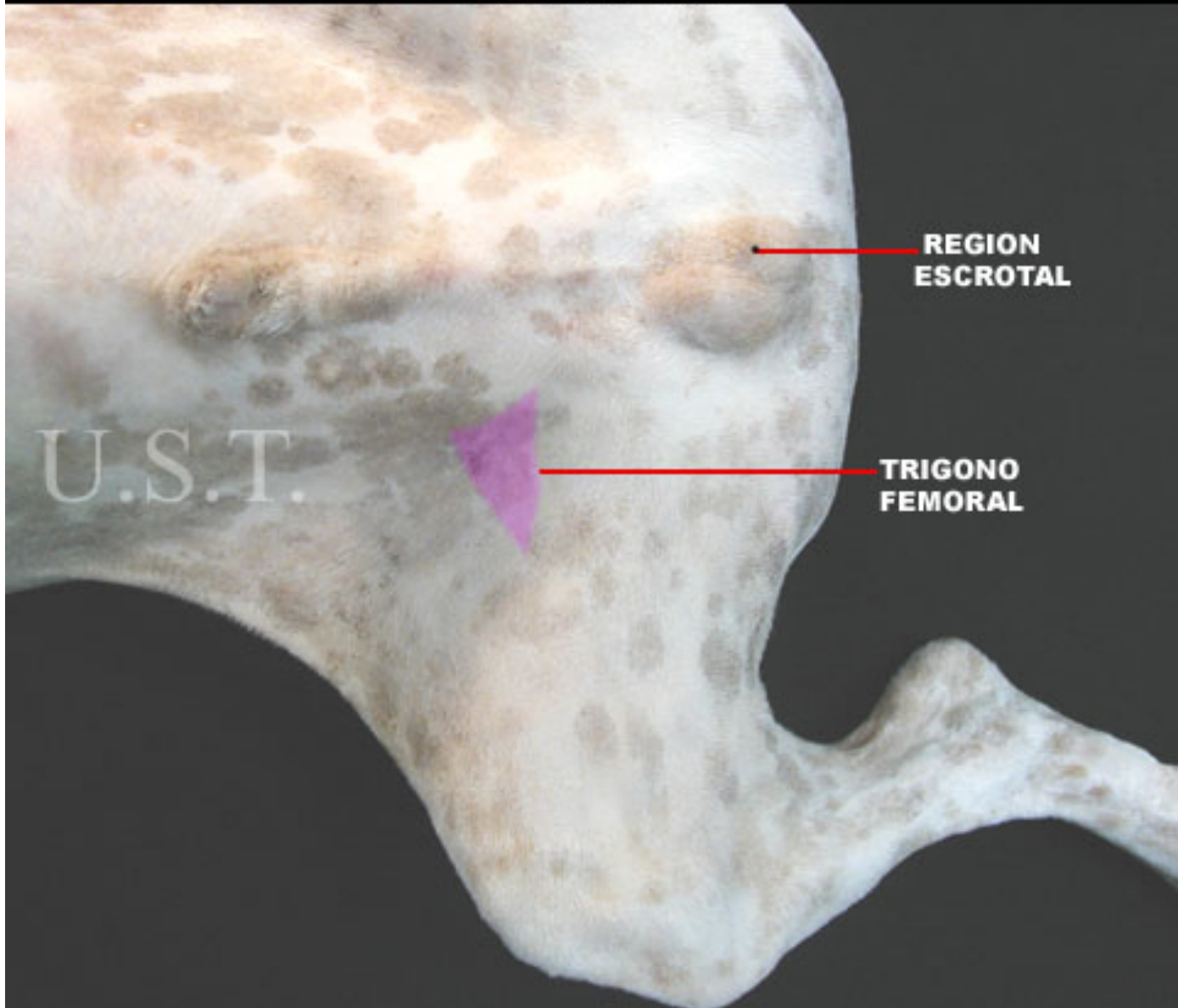
REGION
ANAL

REGION
UROGENITAL

REGION
PERINEAL

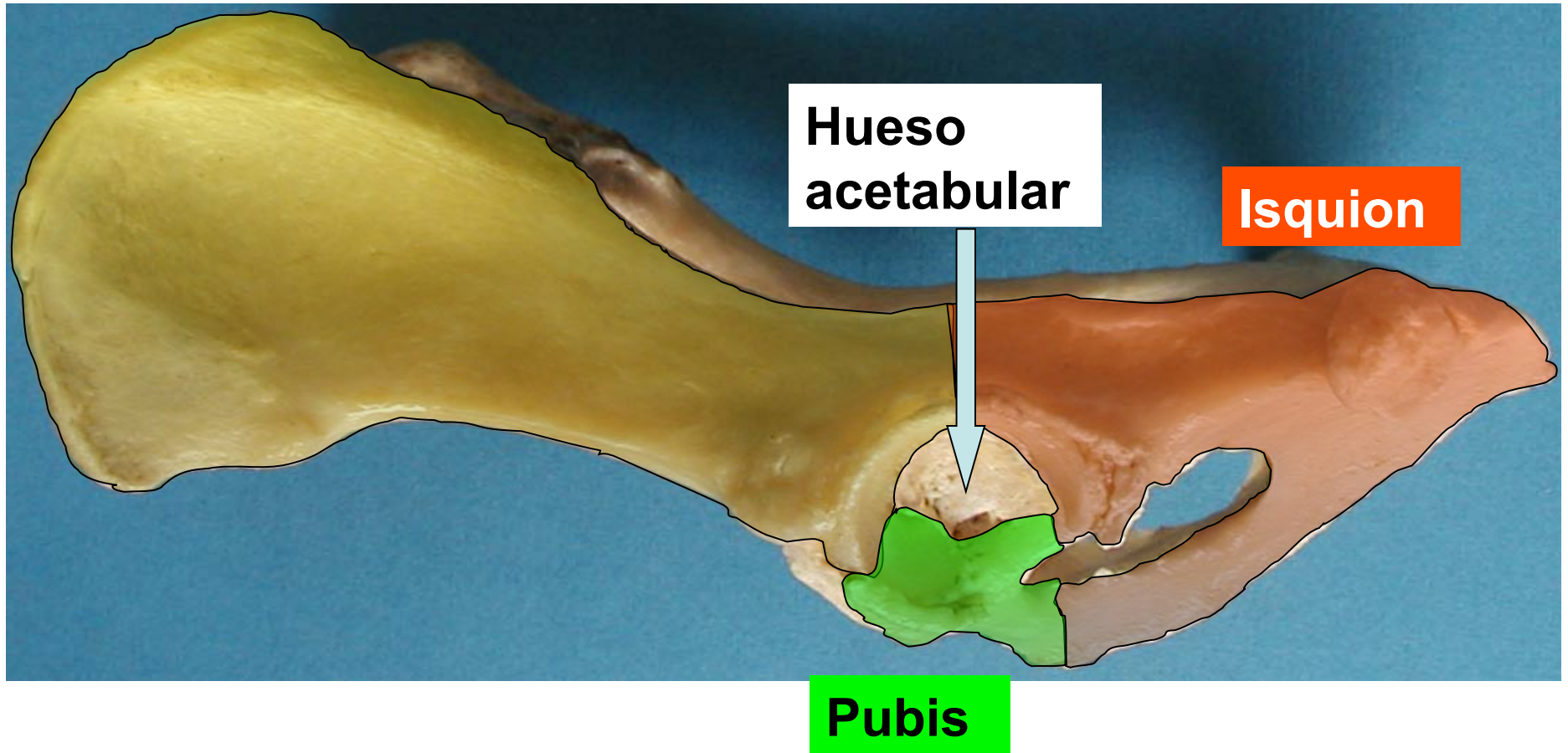


**REGION PELVICA Y MIEMBRO PELVICO DE CANINO
VISTA VENTRAL**

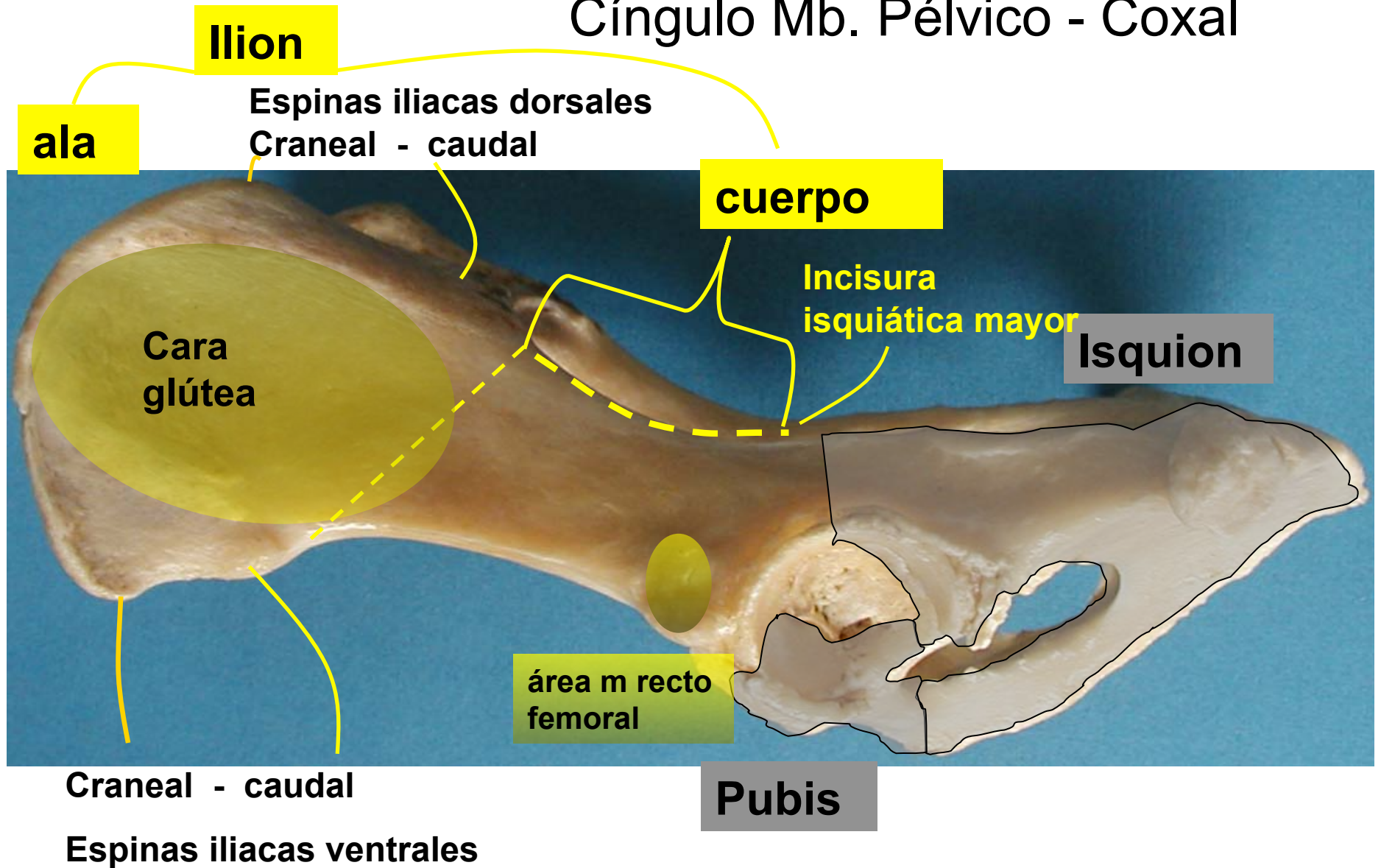


Cíngulo Mb. Pélvico - Coxal

Ilion



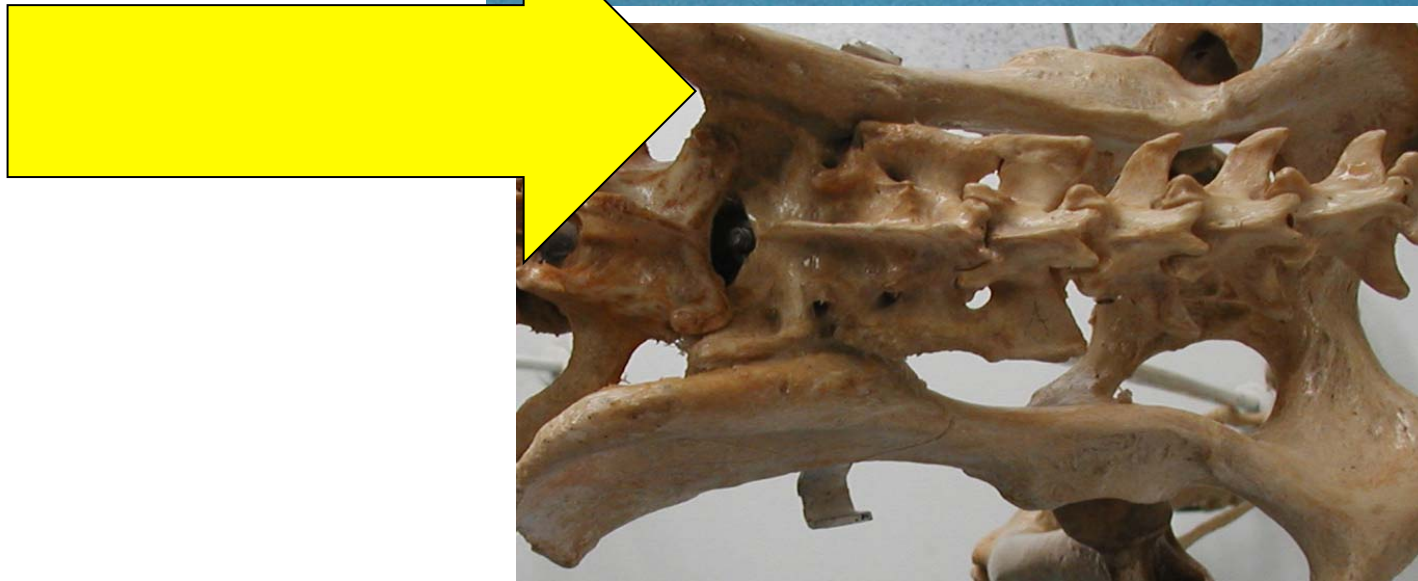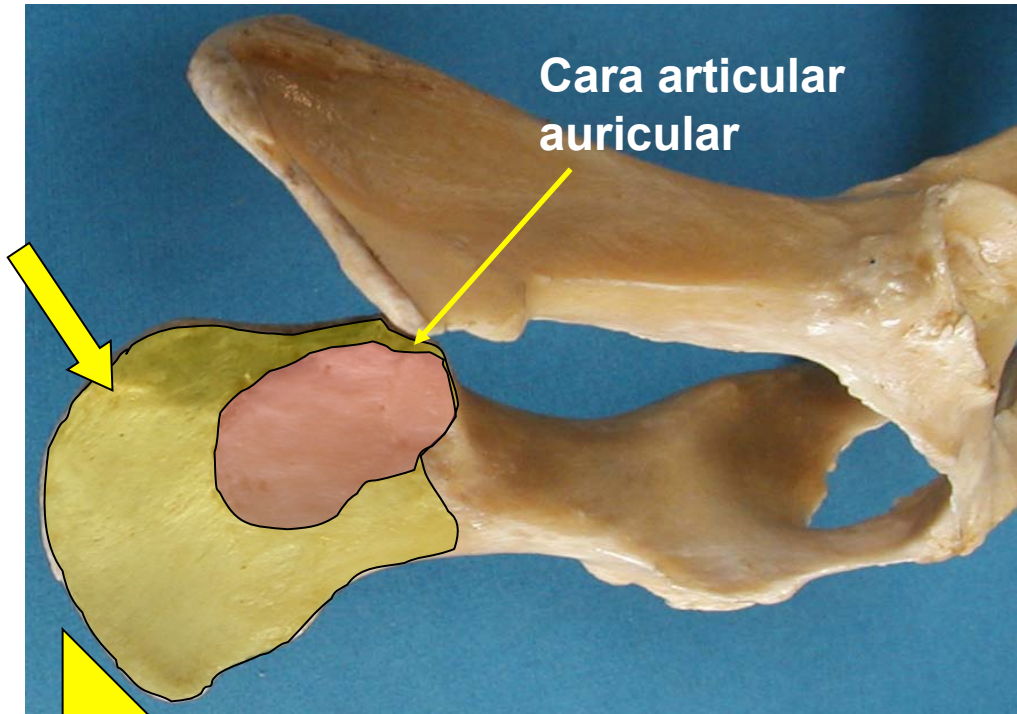
Cíngulo Mb. Pélvico - Coxal



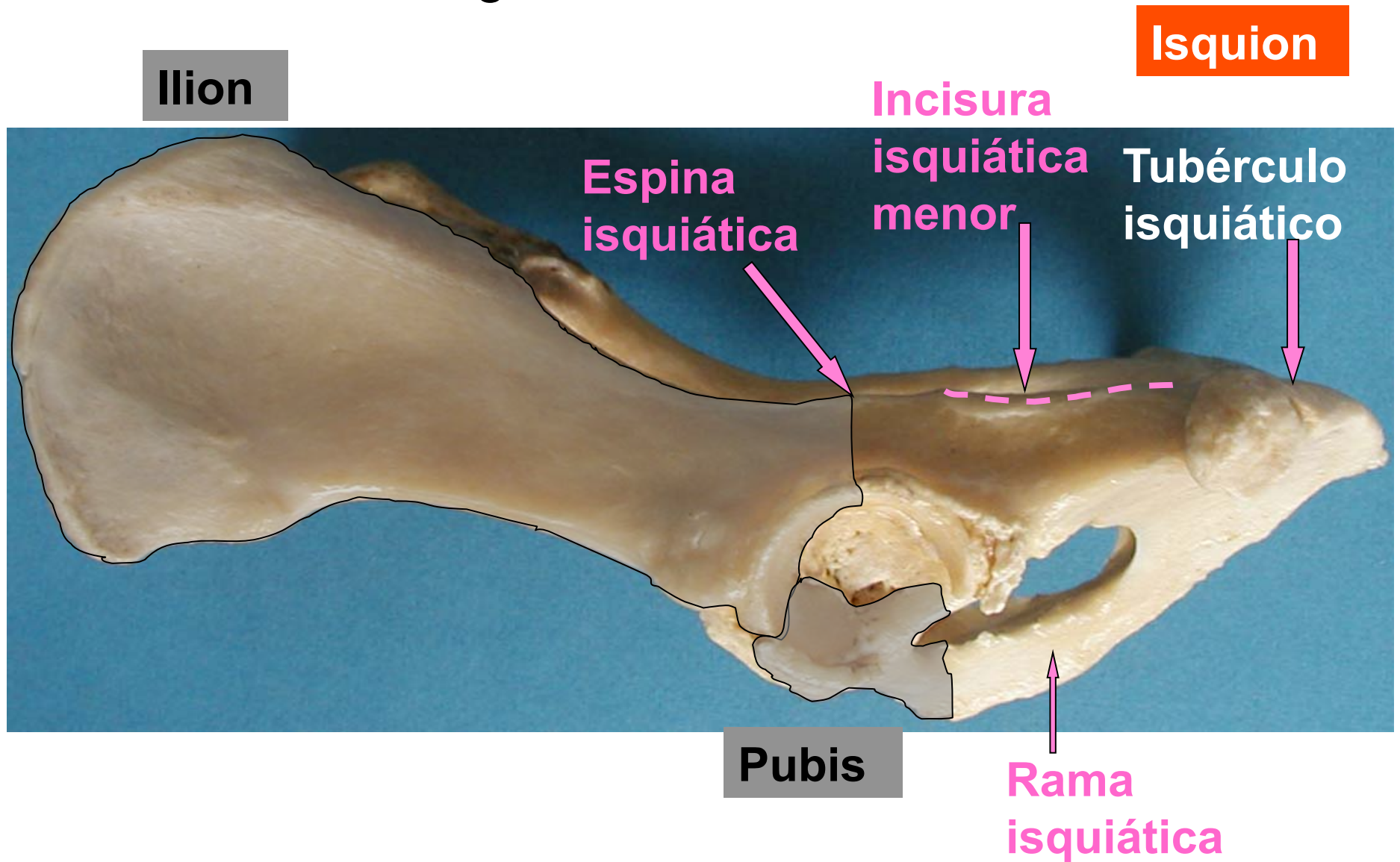
Ilion

Cara sacro
pelviana

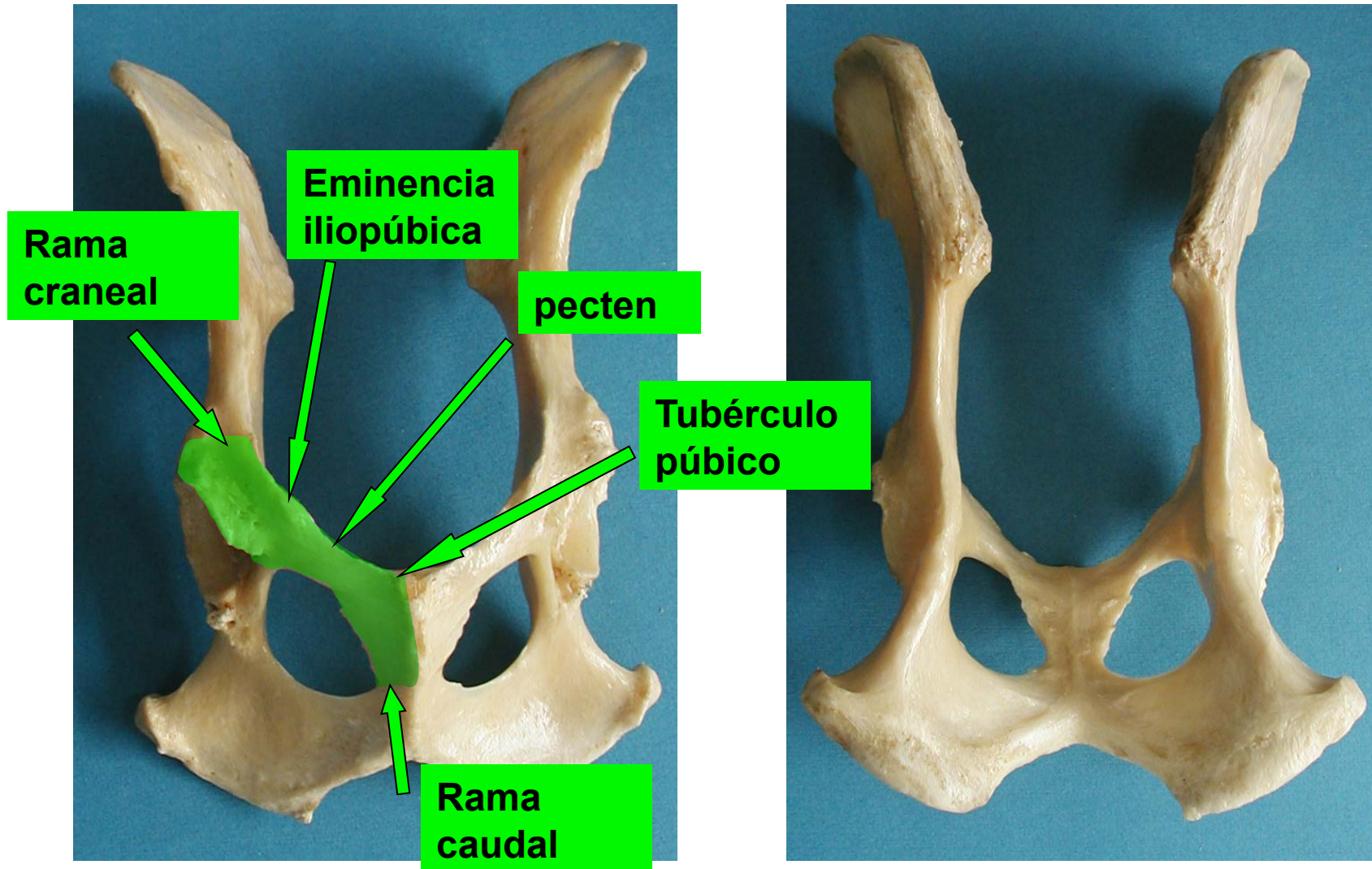
Cara articular
auricular



Cíngulo Mb. Pélvico - Coxal



Pubis



Abertura pélvica craneal

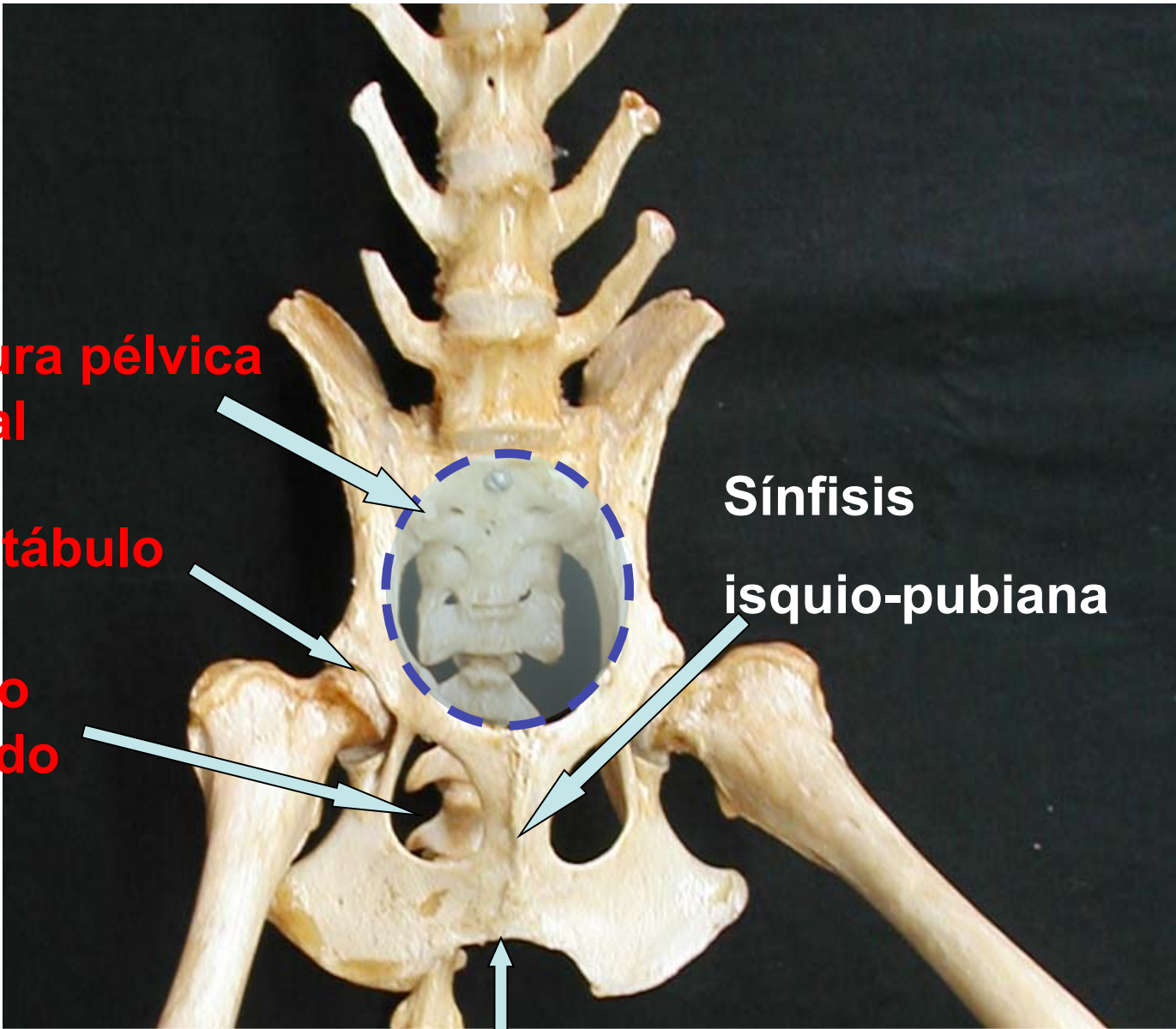
Acetábulo

Agujero obturado

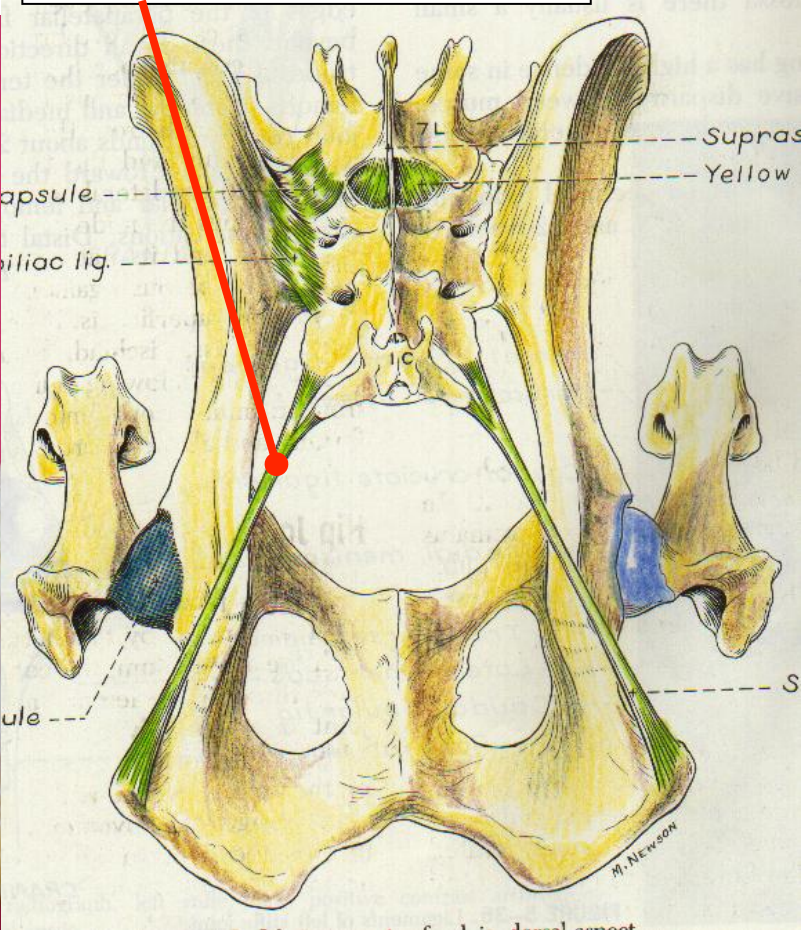
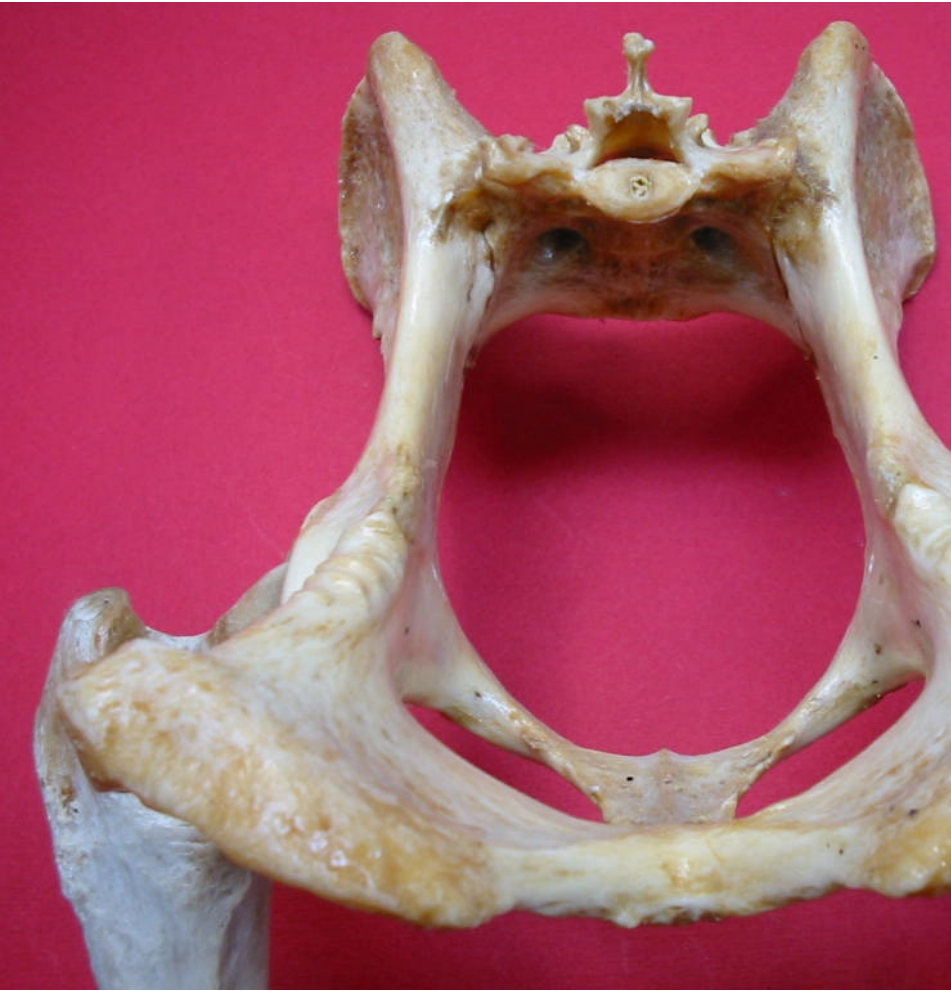Sínfisis

isquio-pubiana

Arco isquiático



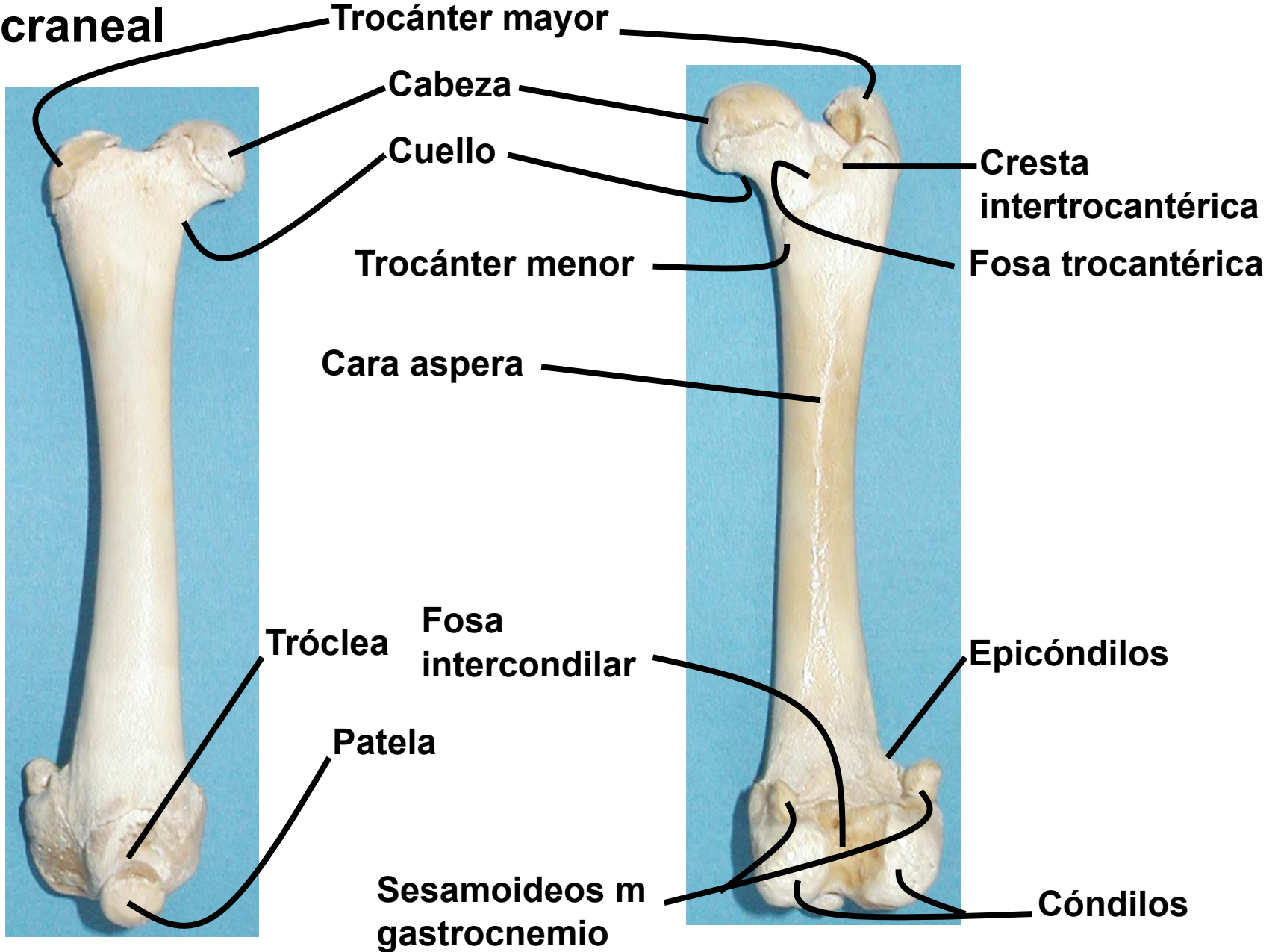
Lig. sacrotuberal



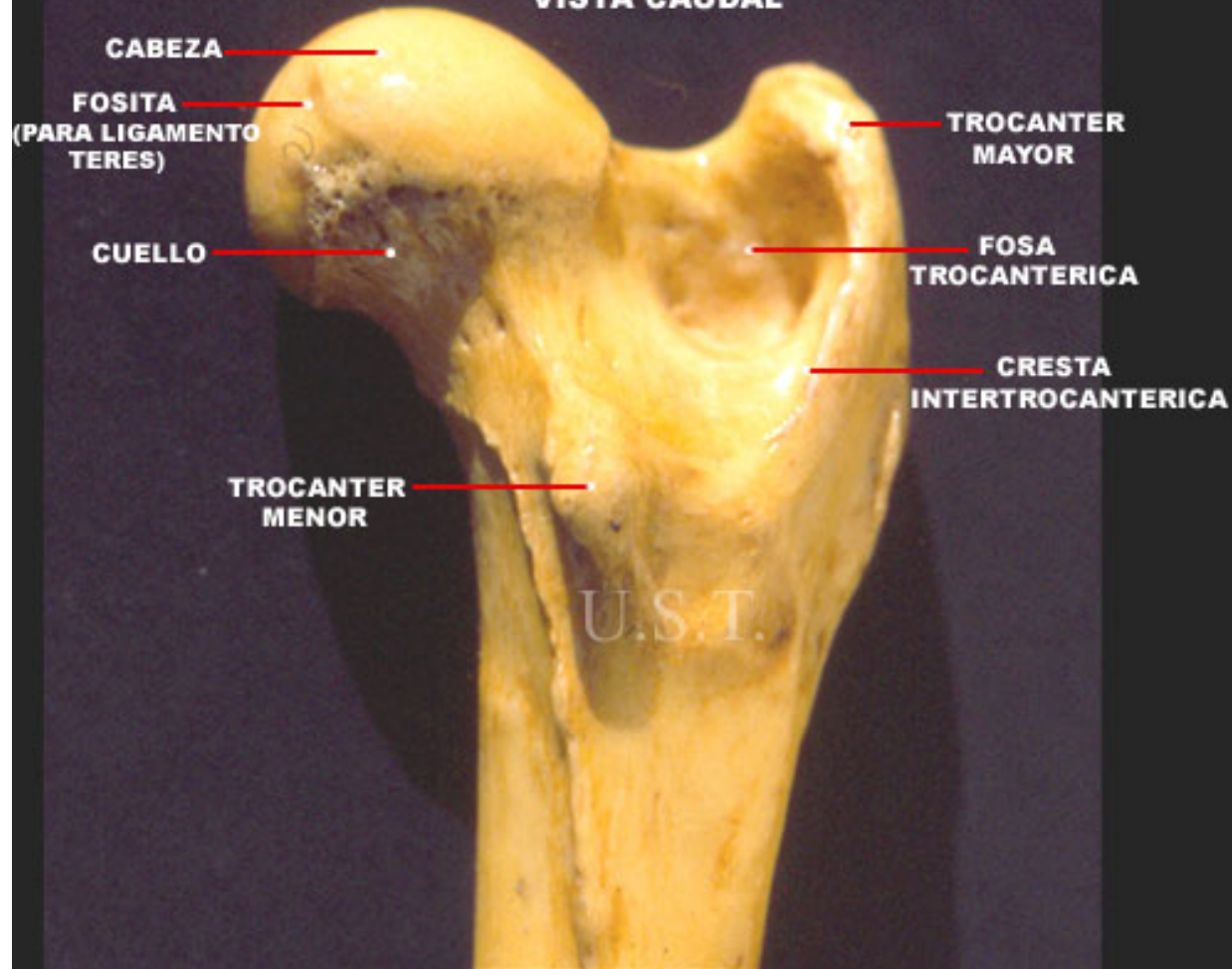
Región femoral

Vista craneal

Vista caudal



**EPIFISIS PROXIMAL DE FEMUR DERECHO DE CANINO
VISTA CAUDAL**



**EPIFISIS DISTAL DE FEMUR
DERECHO DE CANINO
VISTA VENTRO CAUDAL**

U.S.T.

CONDILO MEDIAL

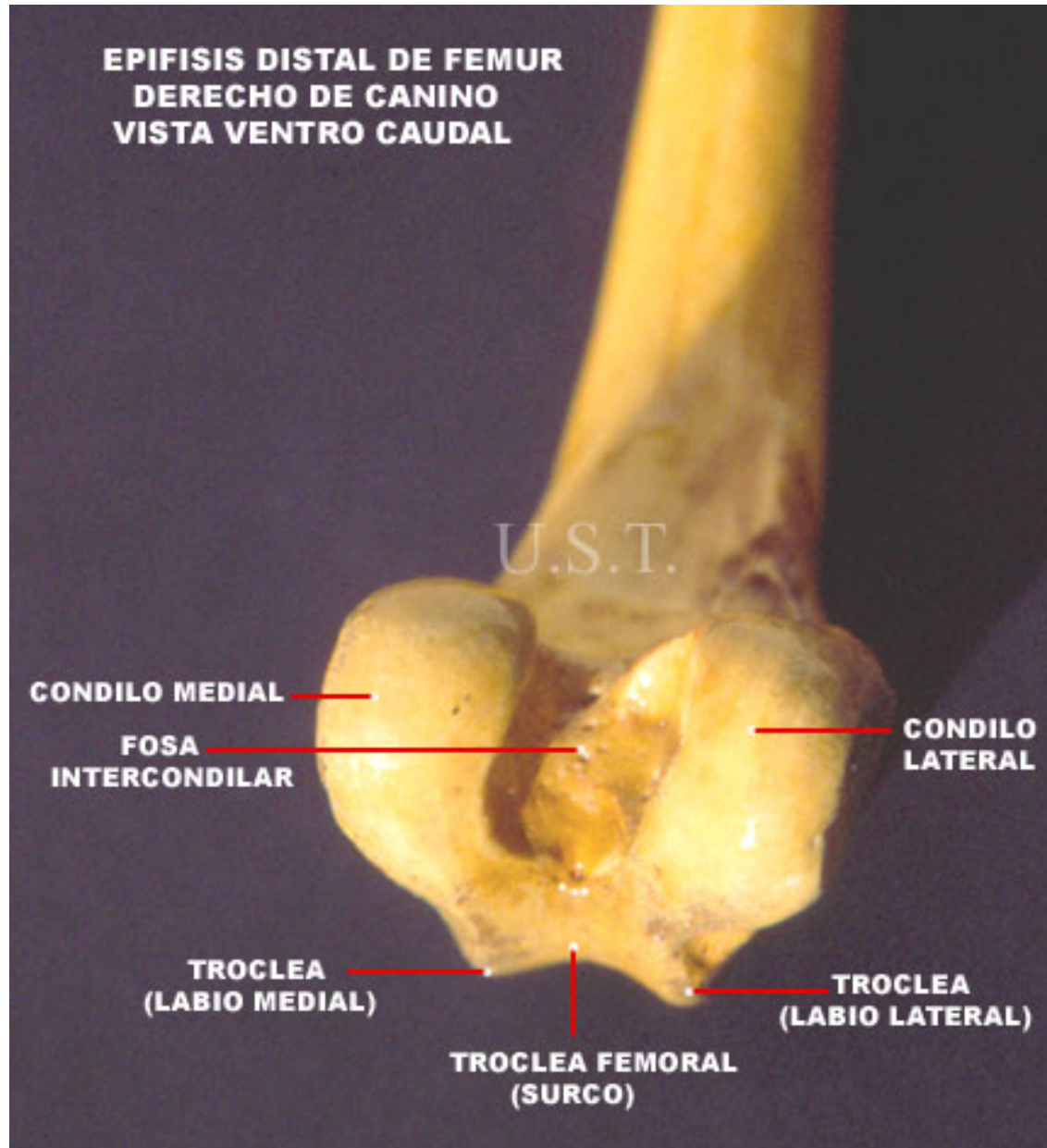
**FOSA
INTERCONDILAR**

**CONDILO
LATERAL**

**TROCLEA
(LABIO MEDIAL)**

**TROCLEA FEMORAL
(SURCO)**

**TROCLEA
(LABIO LATERAL)**



Región tibial

Vista craneal

Vista lateral

Cóndilos tibiales

Surco extensor

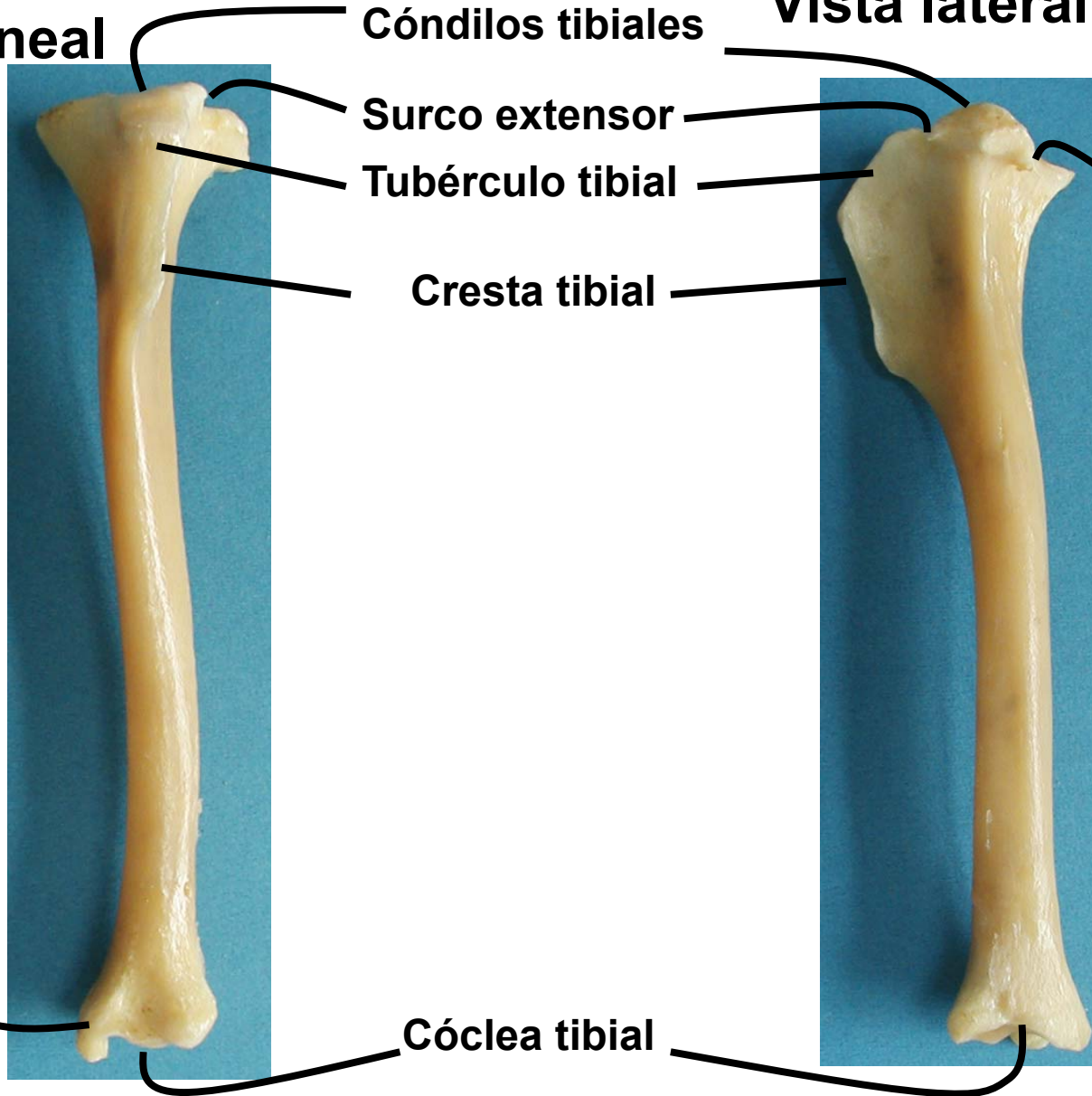
Tubérculo tibial

Cresta tibial

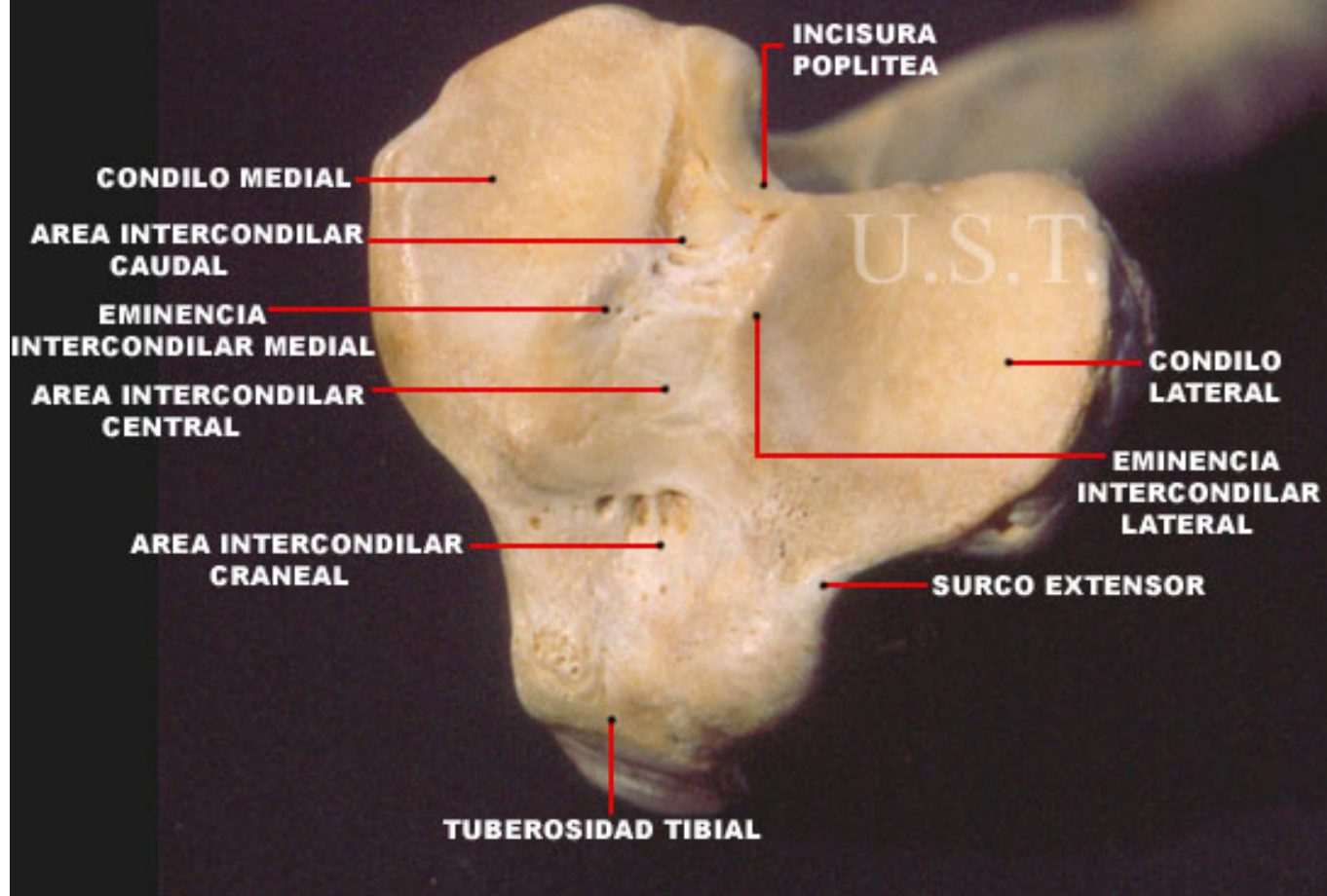
Incisura poplitea

Maleolo tibial

Cóclea tibial



**EPIFISIS PROXIMAL DE TIBIA DERECHA DE CANINO
VISTA PROXIMAL**

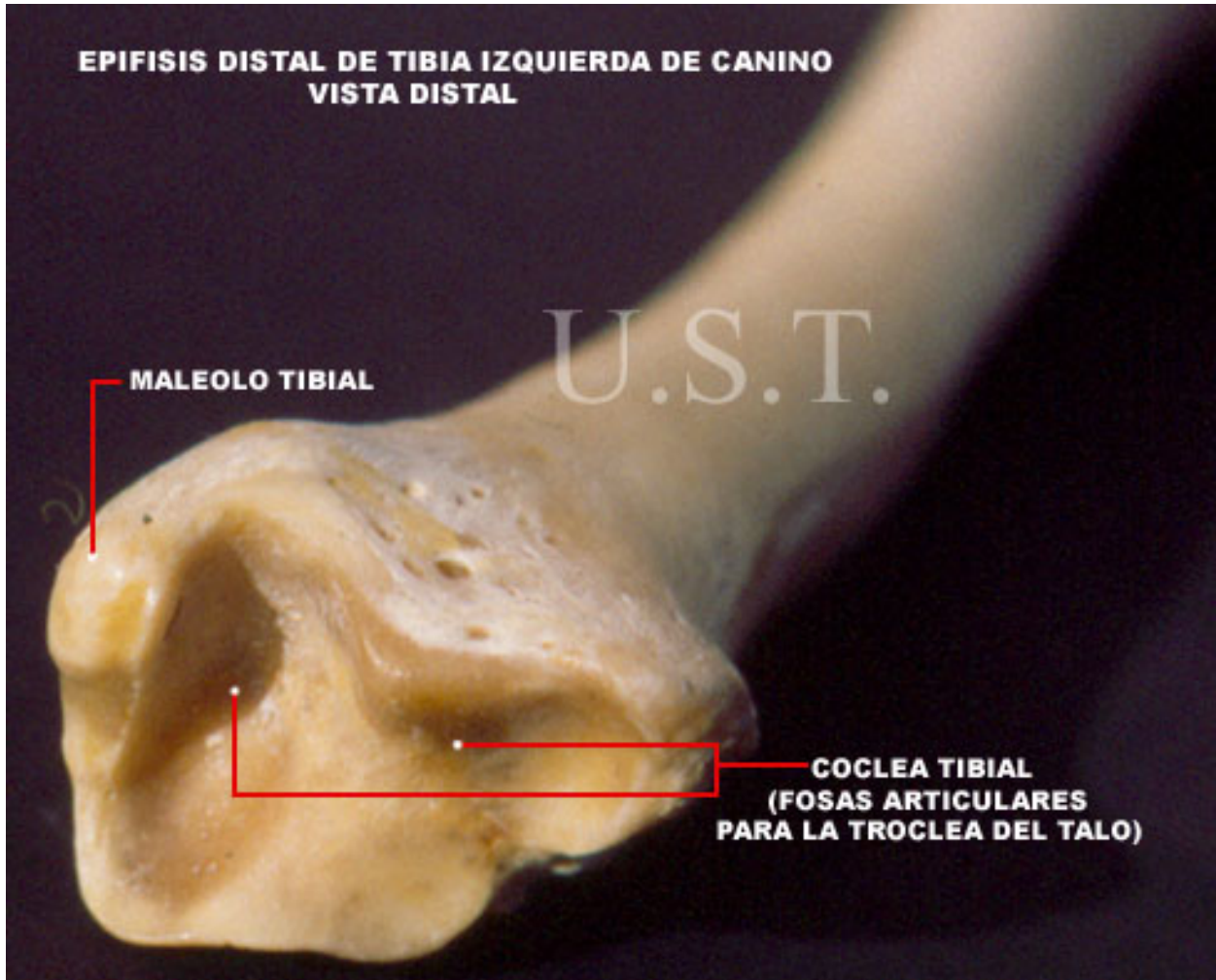


**EPIFISIS DISTAL DE TIBIA IZQUIERDA DE CANINO
VISTA DISTAL**

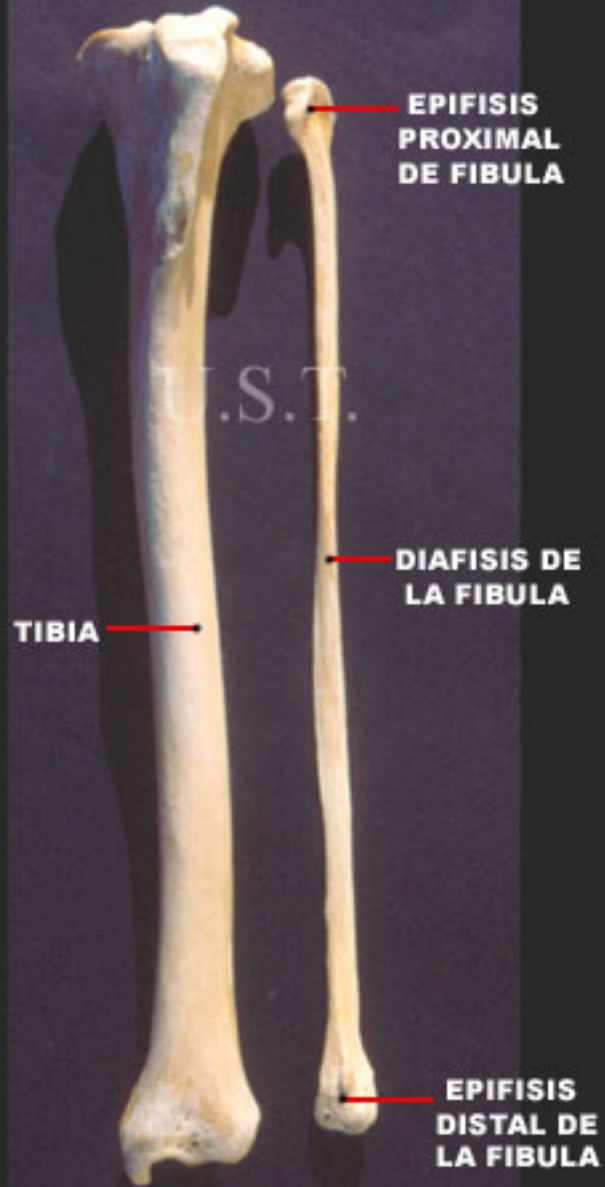U.S.T.

MALEOLO TIBIAL

**COCLEA TIBIAL
(FOSAS ARTICULARES
PARA LA TROCLEA DEL TALO)**

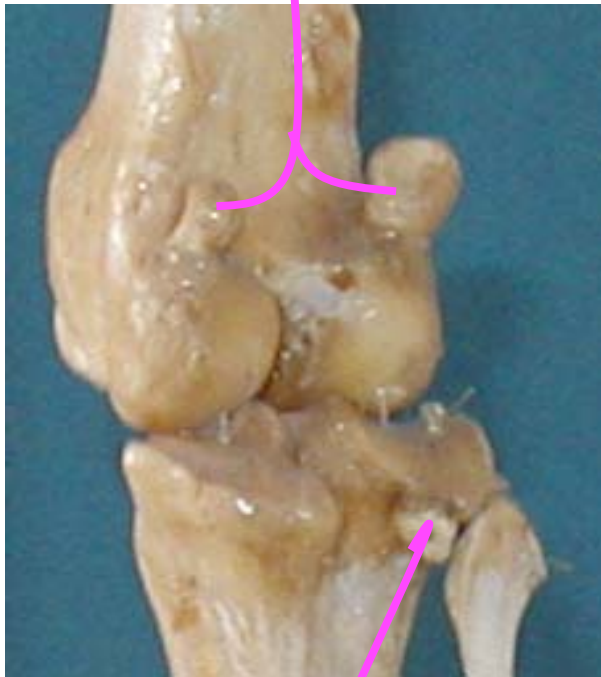


**TIBIA Y FIBULA IZQUIERDA DE CANINO
VISTA CRANEAL**

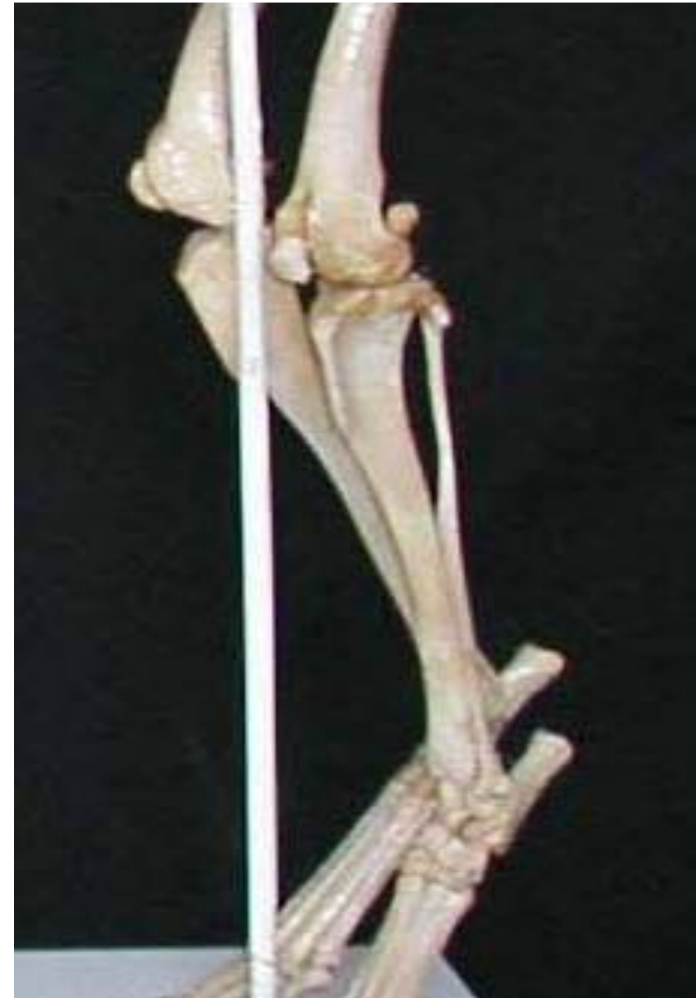



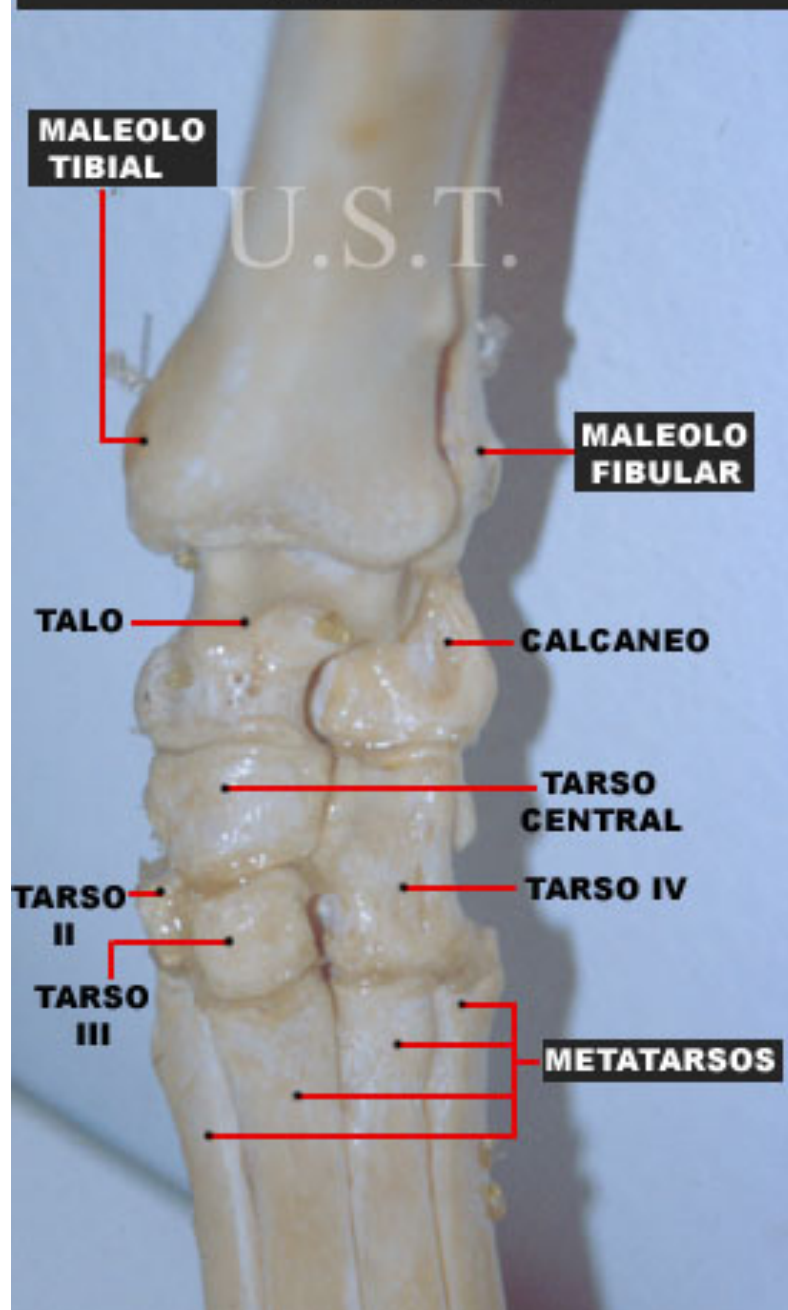
**Sesamoideos m
gastrocnemio**



**Sesamoideo m
popliteo**



TARSO IZQUIERDO DE CANINO VISTA DORSAL



**PIE IZQUIERDO DE CANINO
VISTA CAUDAL**

**TUBEROSIDAD
CALCANEA**

CALCANEAO

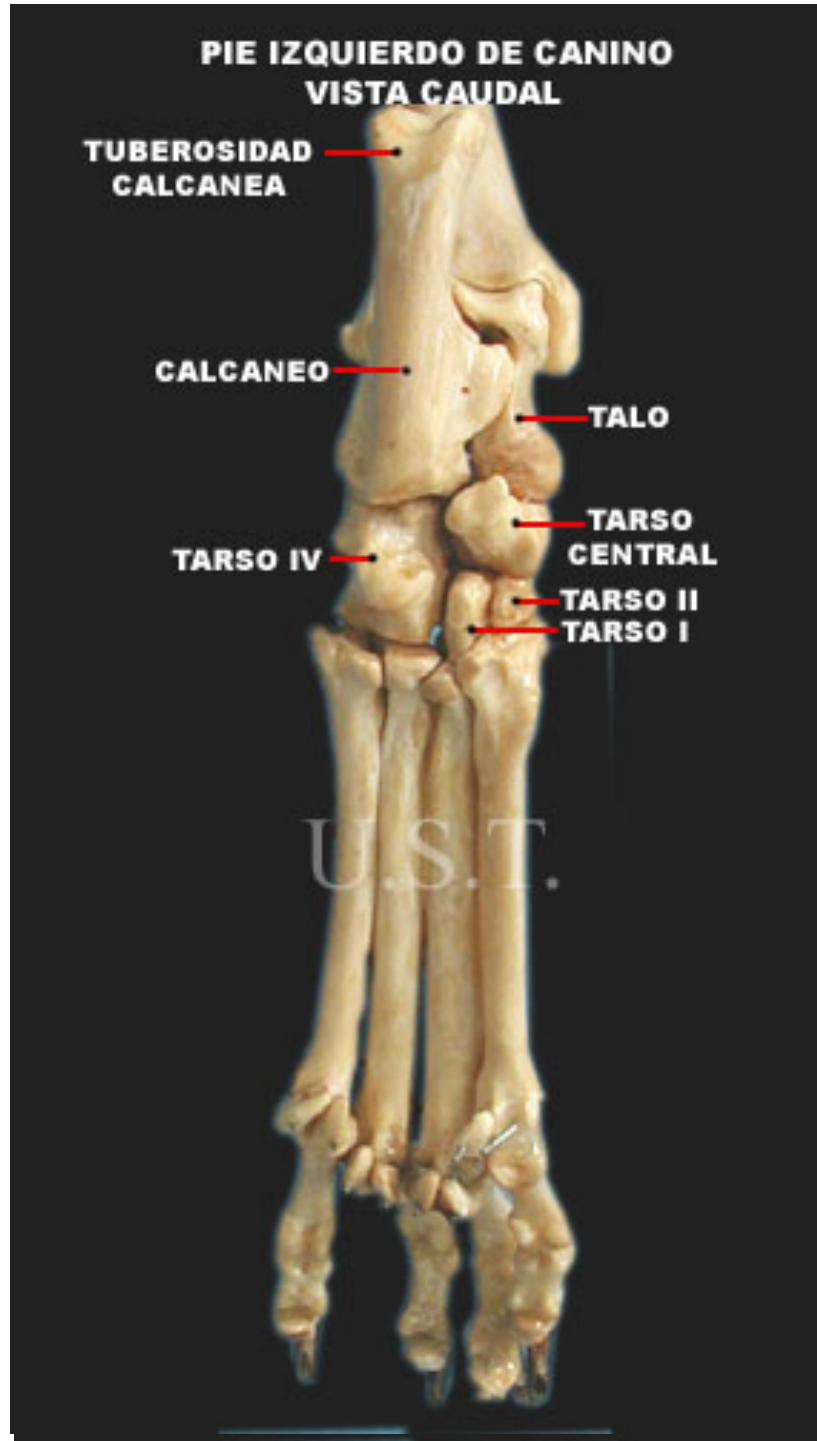
TALO

TARSO IV

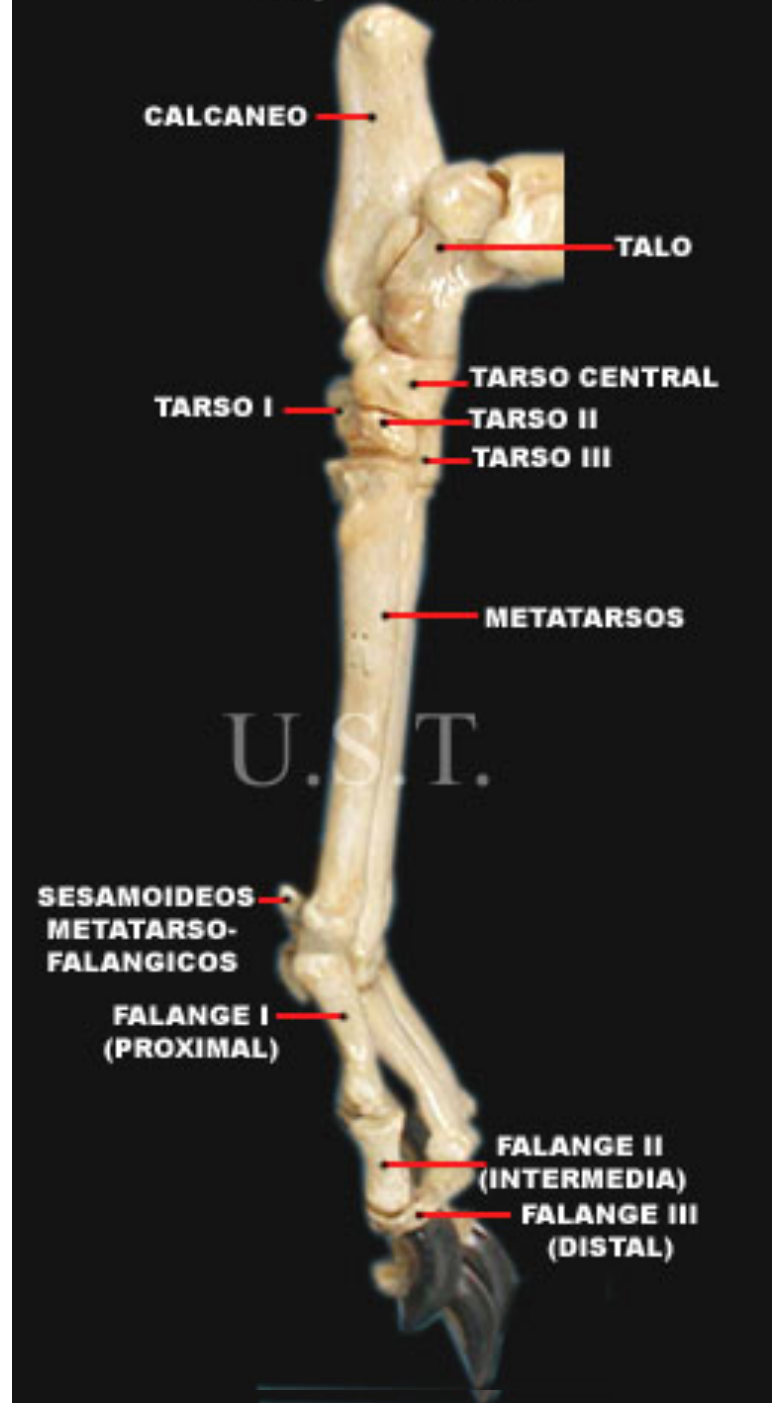**TARSO
CENTRAL**

**TARSO II
TARSO I**

U.S.T.



**PIE IZQUIERDO DE CANINO
VISTA MEDIAL**



CALCANEAO

TALO

TARSO I

TARSO CENTRAL

TARSO II

TARSO III

METATARROSOS

U.S.T.

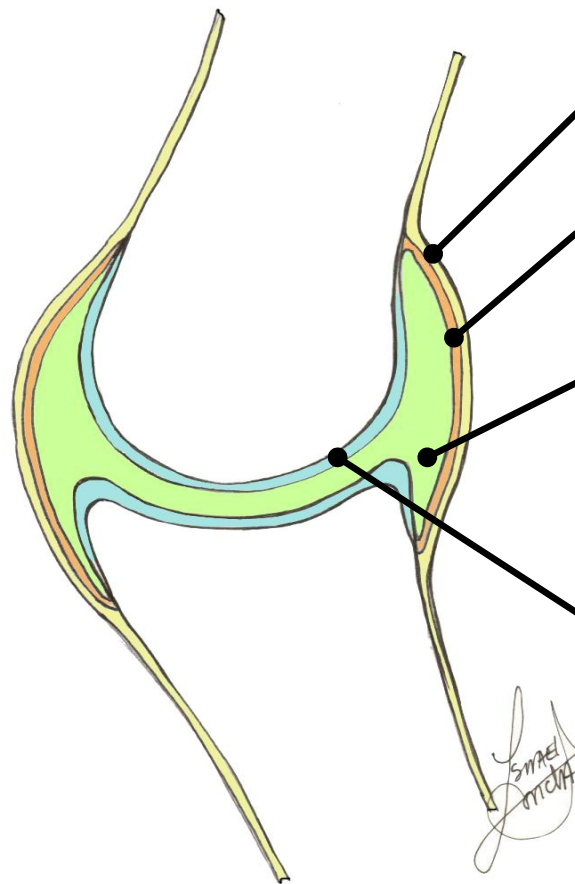
**SESAMOIDEOS
METATARSO-
FALANGICOS**

**FALANGE I
(PROXIMAL)**

**FALANGE II
(INTERMEDIA)**

**FALANGE III
(DISTAL)**

ARTICULACIONES SINOVIALES



Cápsula articular



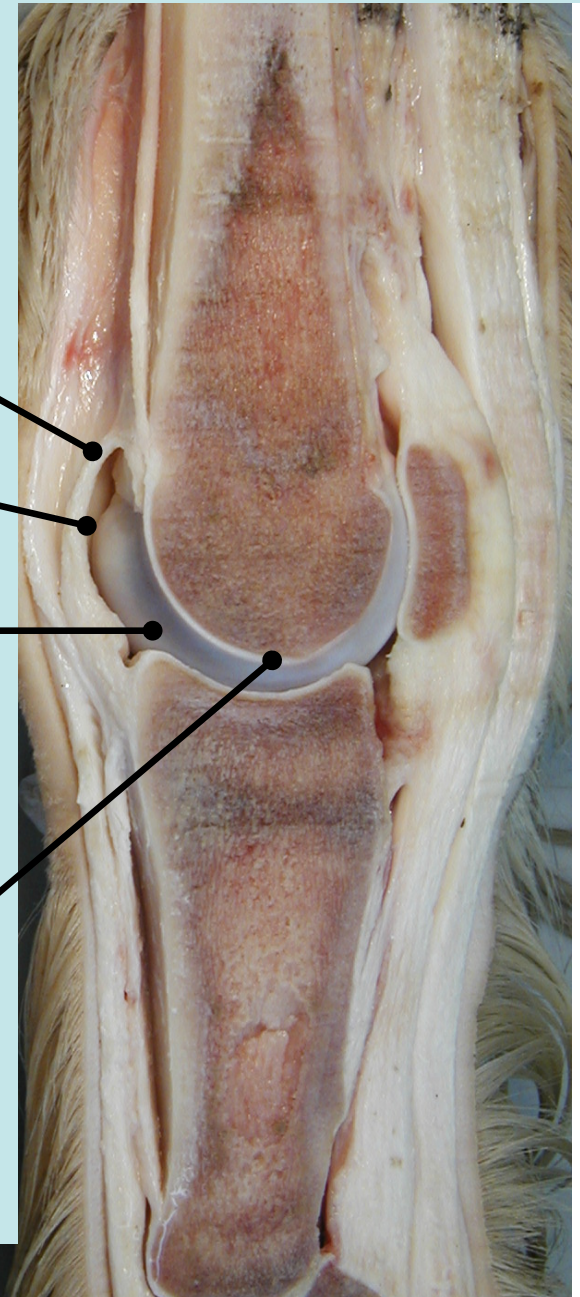
Estrato fibroso

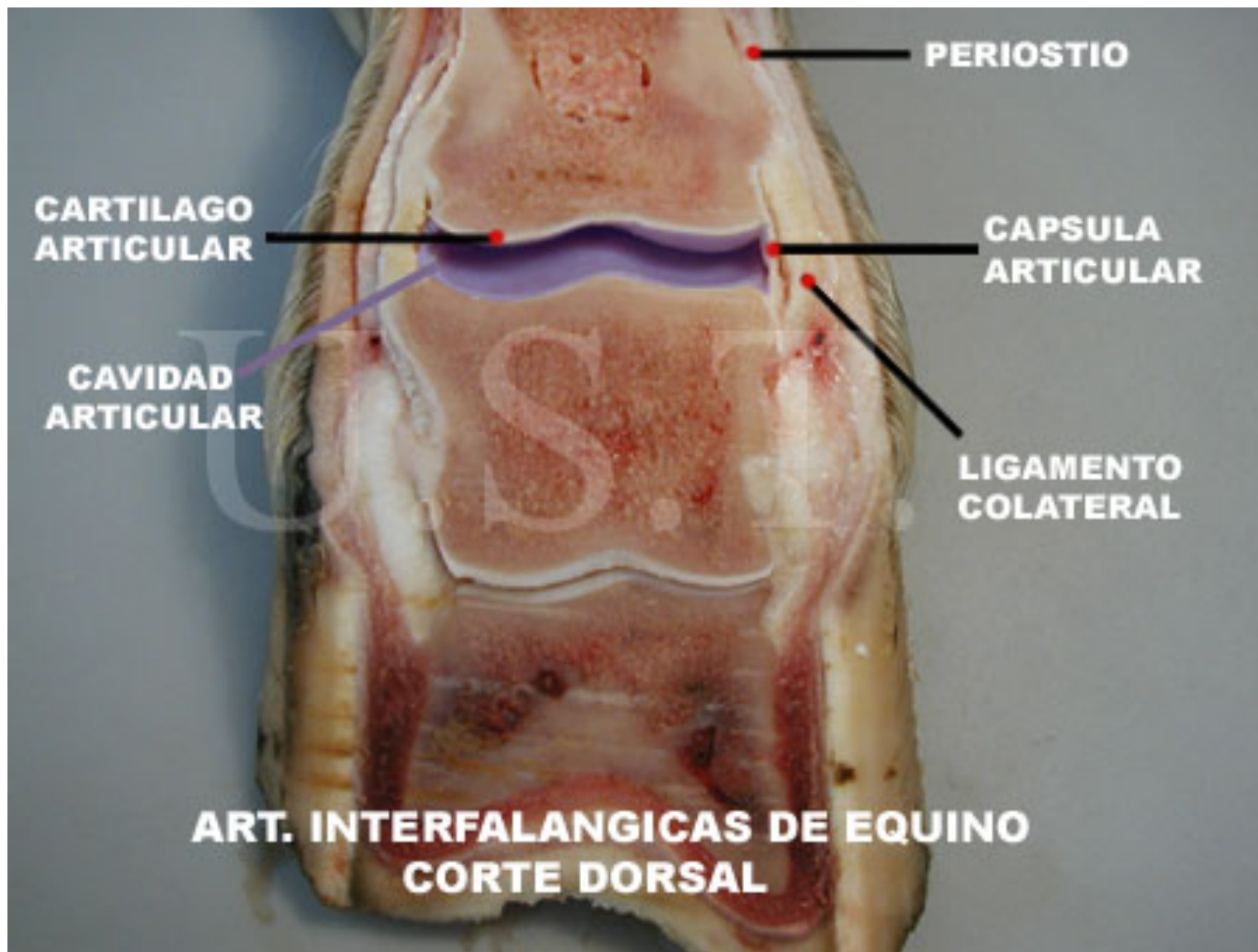


Estrato sinovial

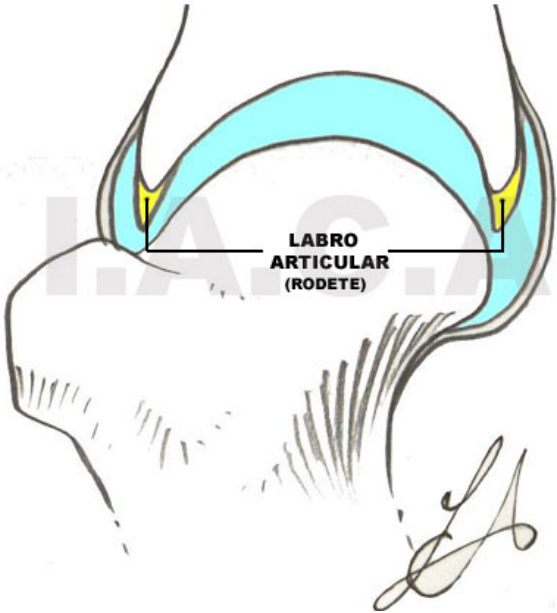
Cavidad articular
con líquido sinovial

Cartílago articular

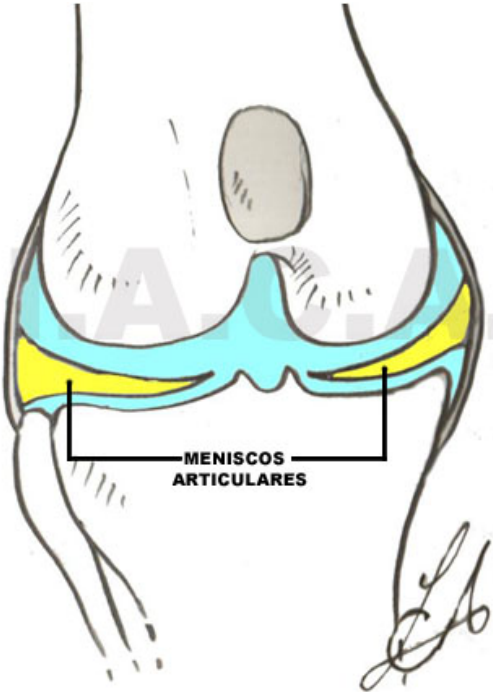




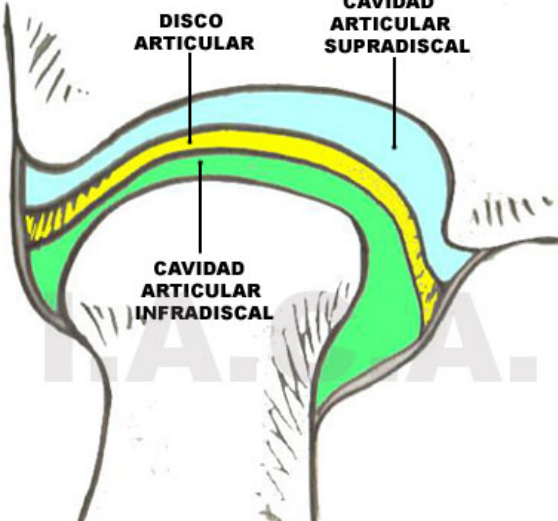
LABRO O RODETE



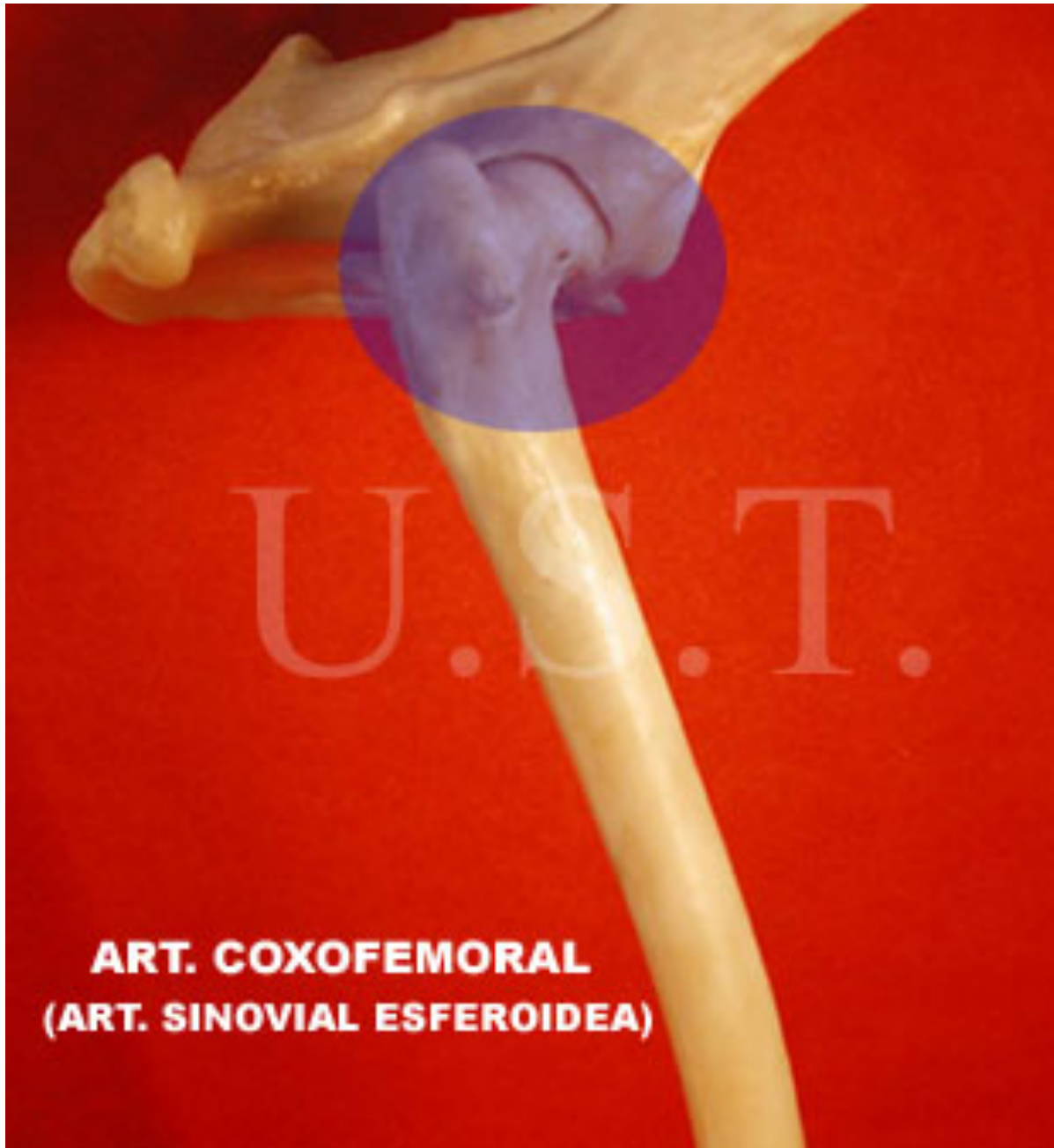
MENISCO



DISCO ARTICULAR
CAVIDAD ARTICULAR SUPRADISCAL

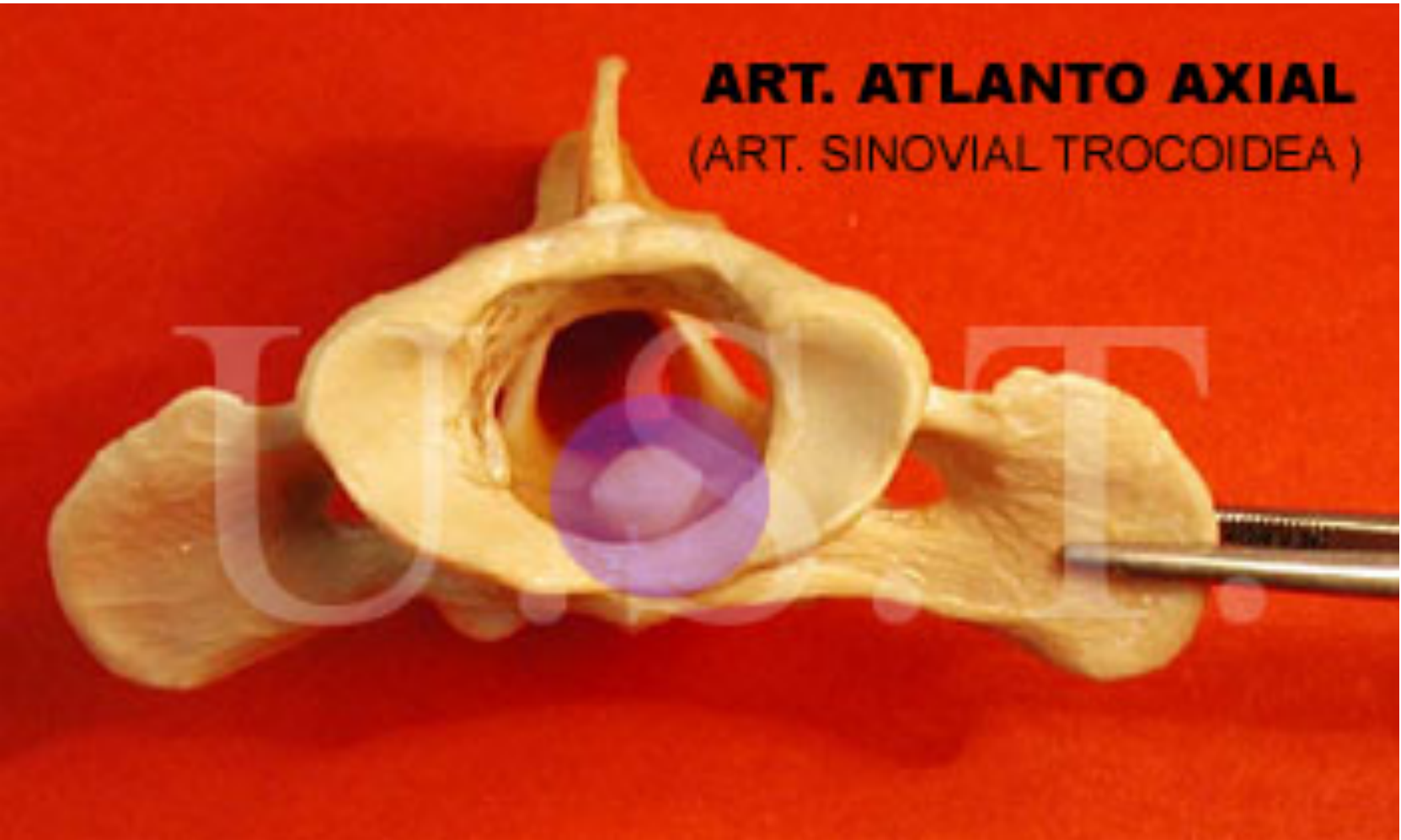


DISCO



ART. COXOFEMORAL
(ART. SINOVIAL ESFEROIDEA)

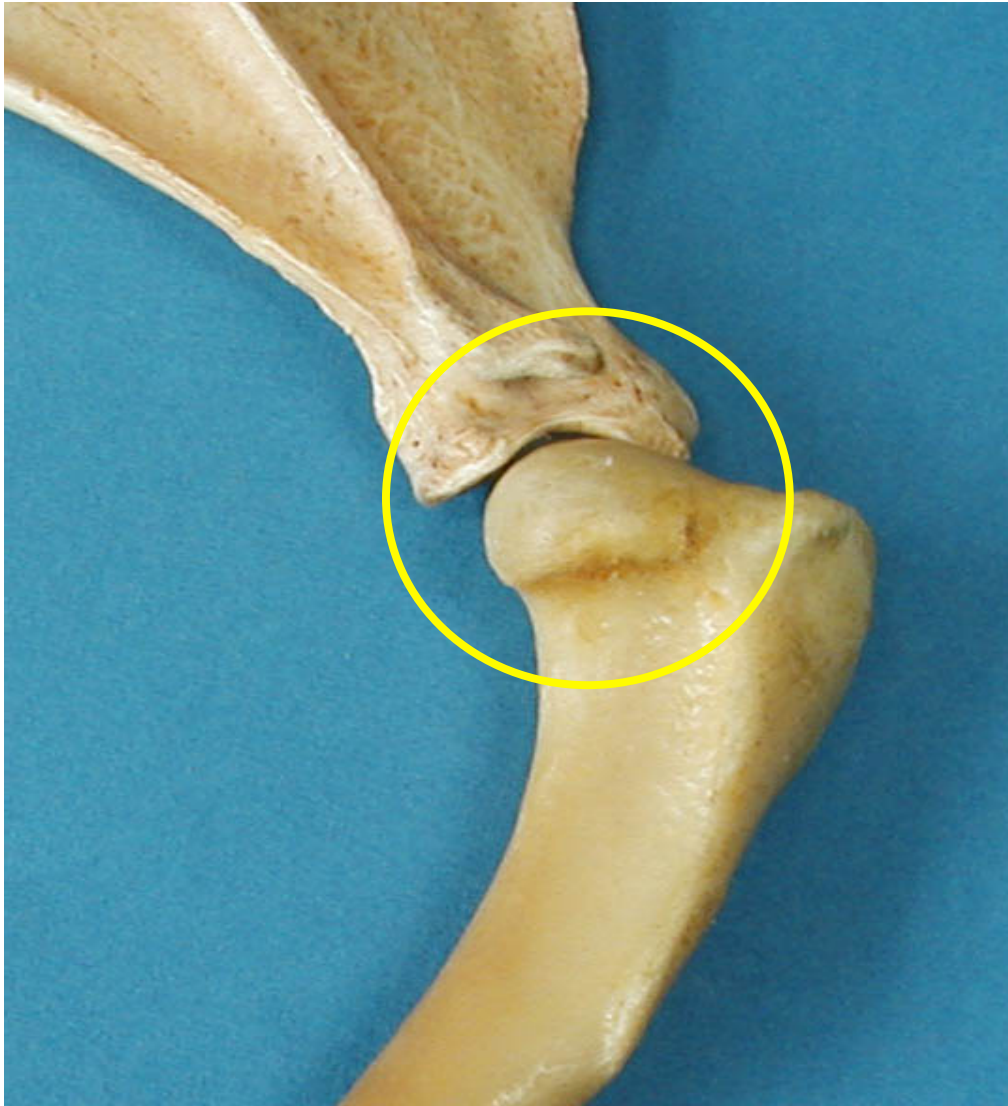
ART. ATLANTO AXIAL
(ART. SINOVIAL TROCOIDEA)



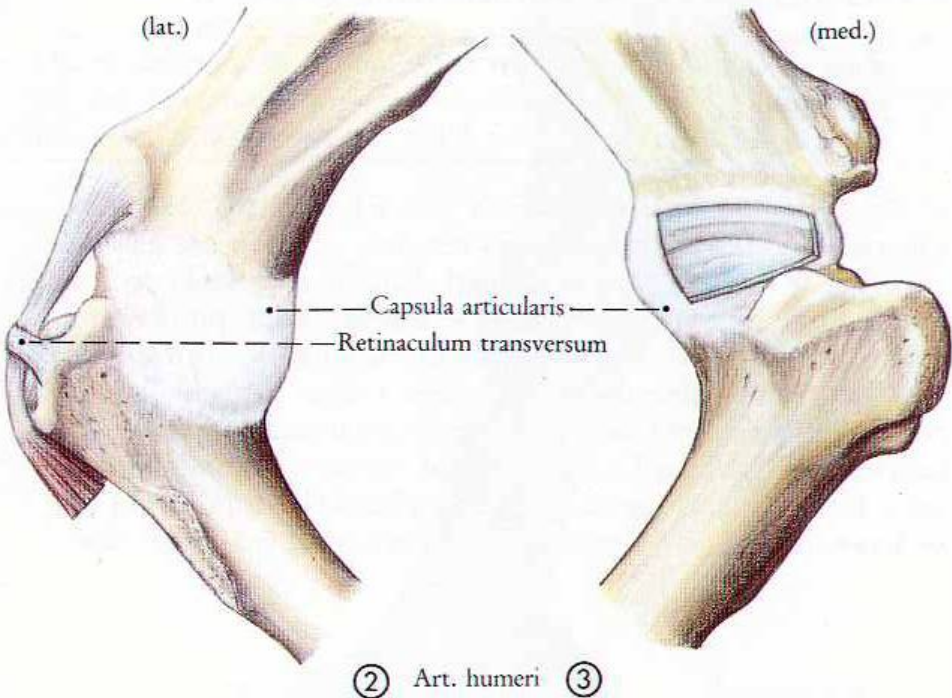
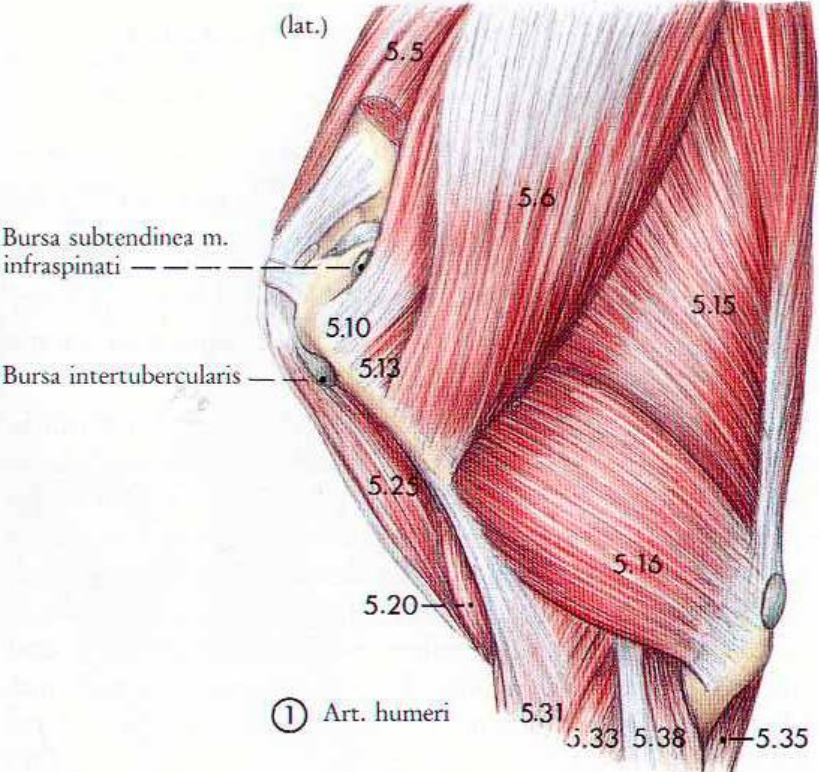


ART. CUBITAL
(ART. SINOVIAL GINGLIMO)

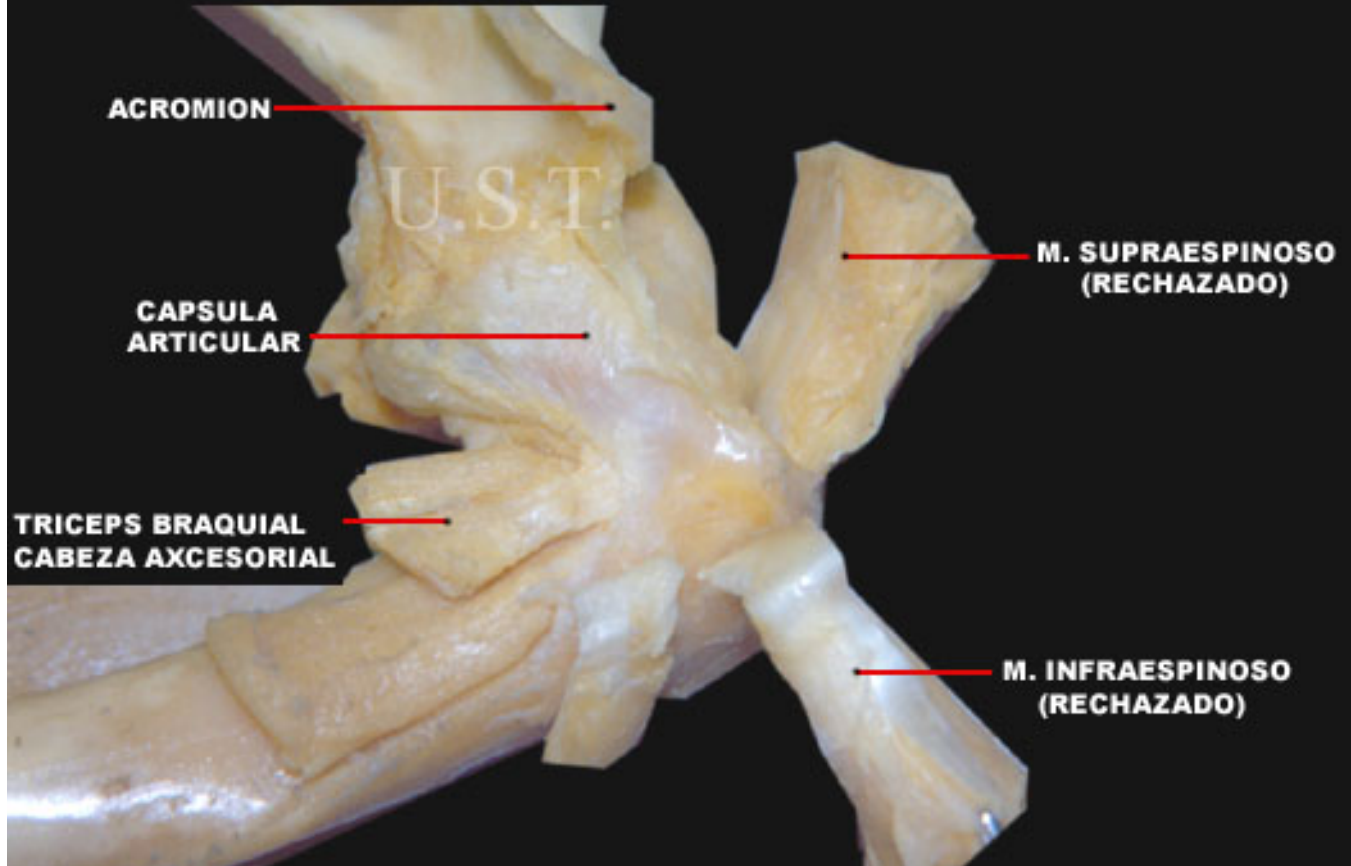
Articulación humeral (hombro)



Juncturae (Articulationes), Bursae et Vaginae synoviales



**ARTICULACION HUMERAL (HOMBRO) DERECHO DE CANINO
VISTA LATERAL, SE HAN EXTRAIDO O RECHAZADO LOS MUSCULOS DE LA REGION**



**ARTICULACION HUMERAL DERECHA DE CANINO
VISTA LATERAL, SE HAN RECHAZADO LOS MUSCULOS
Y SECCIONADO LA CAPSULA ARTICULAR**

**LABRO
GLENOIDEO
CAVIDAD
GLENOIDEA**

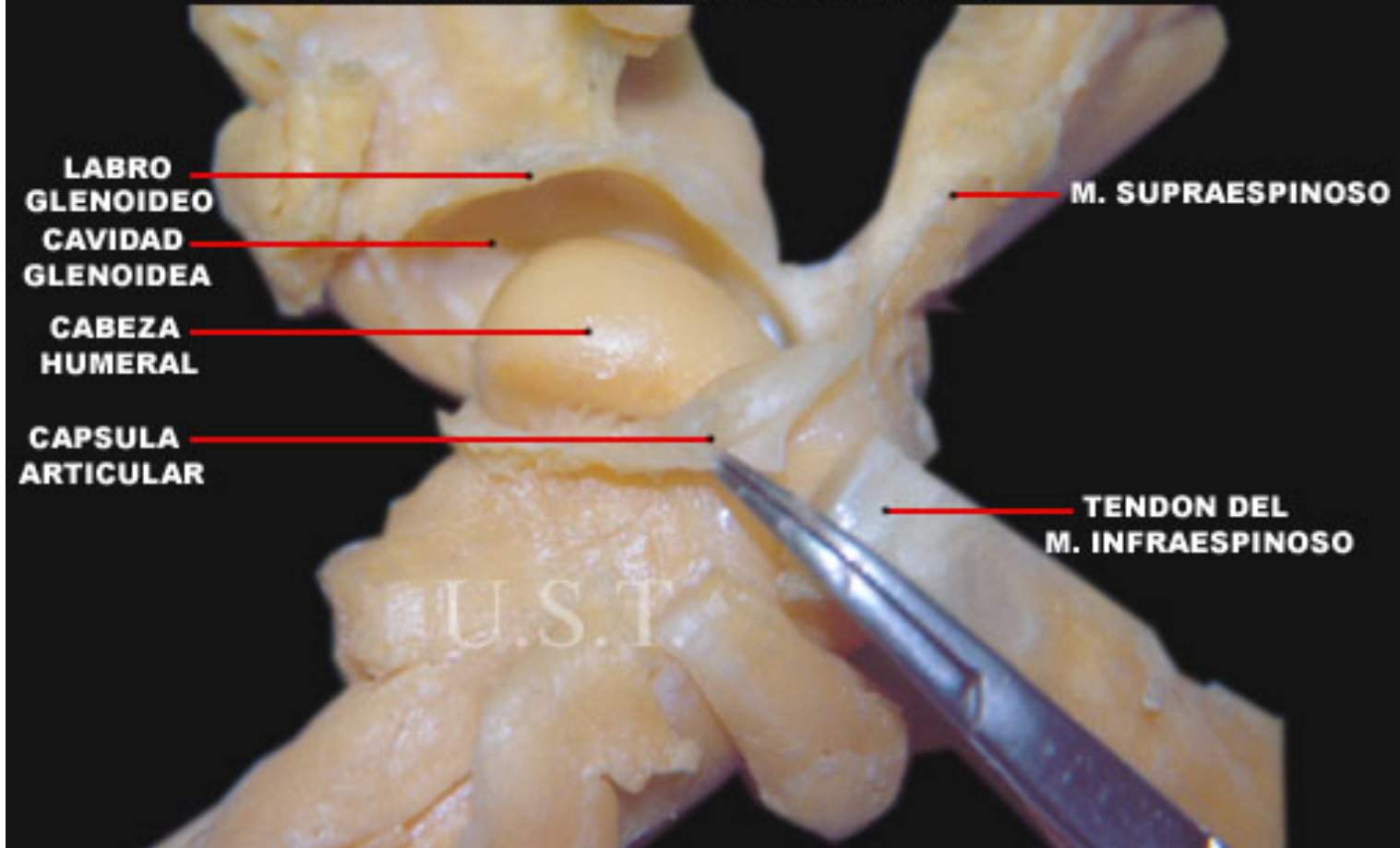
**CABEZA
HUMERAL**

**CAPSULA
ARTICULAR**

M. SUPRAESPINOSO

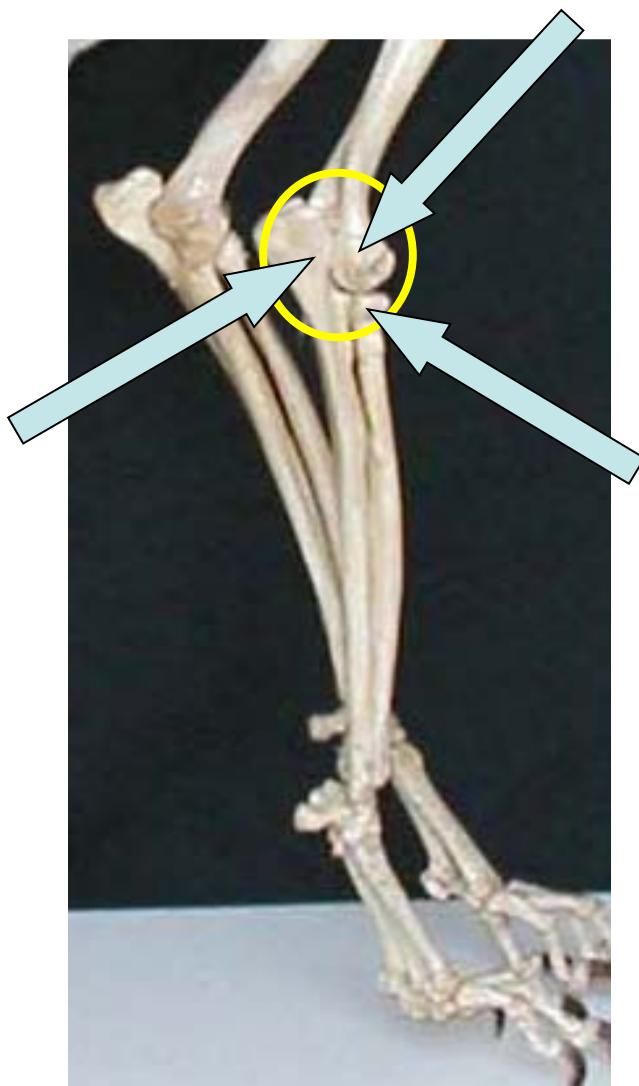
**TENDON DEL
M. INFRAESPINOSO**

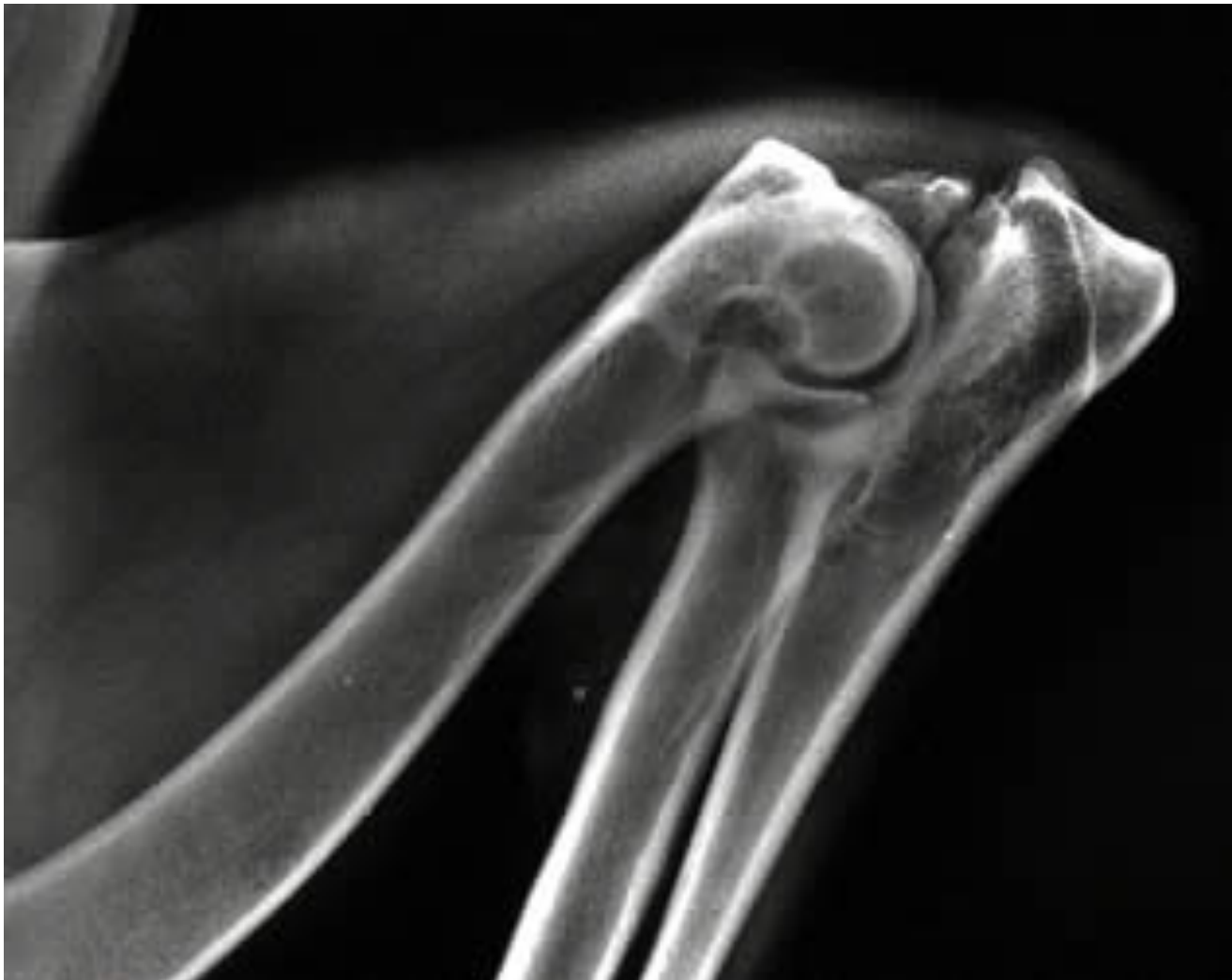
U.S.T



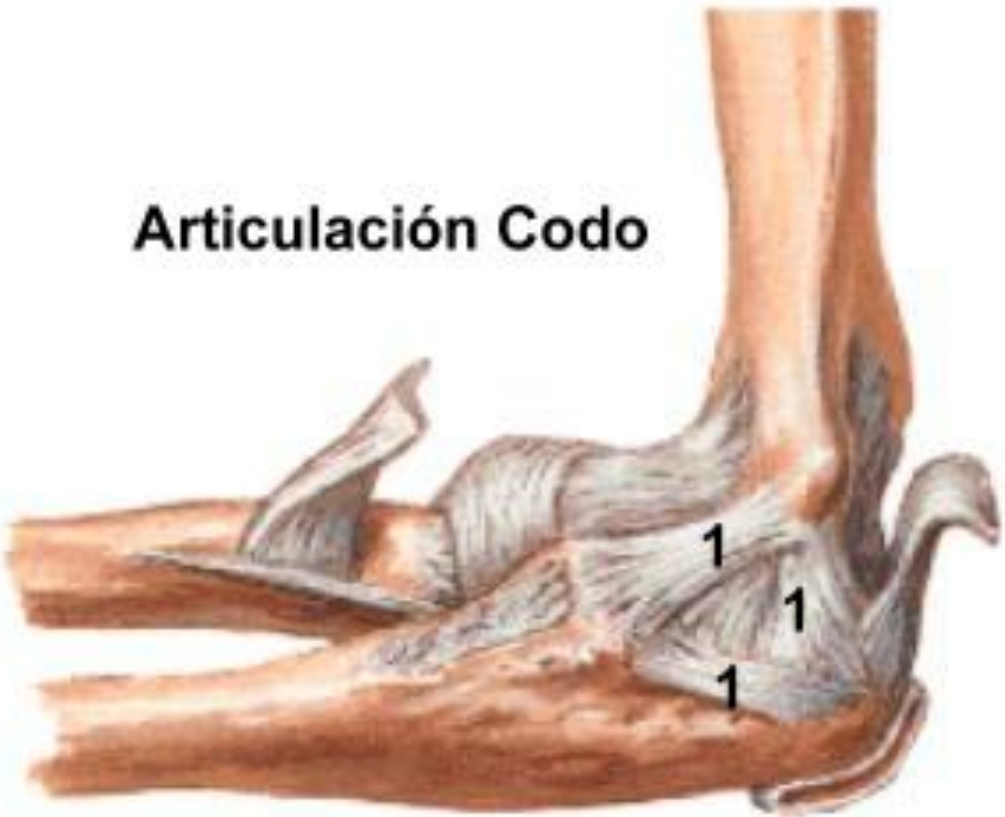


Articulación cubital-codo

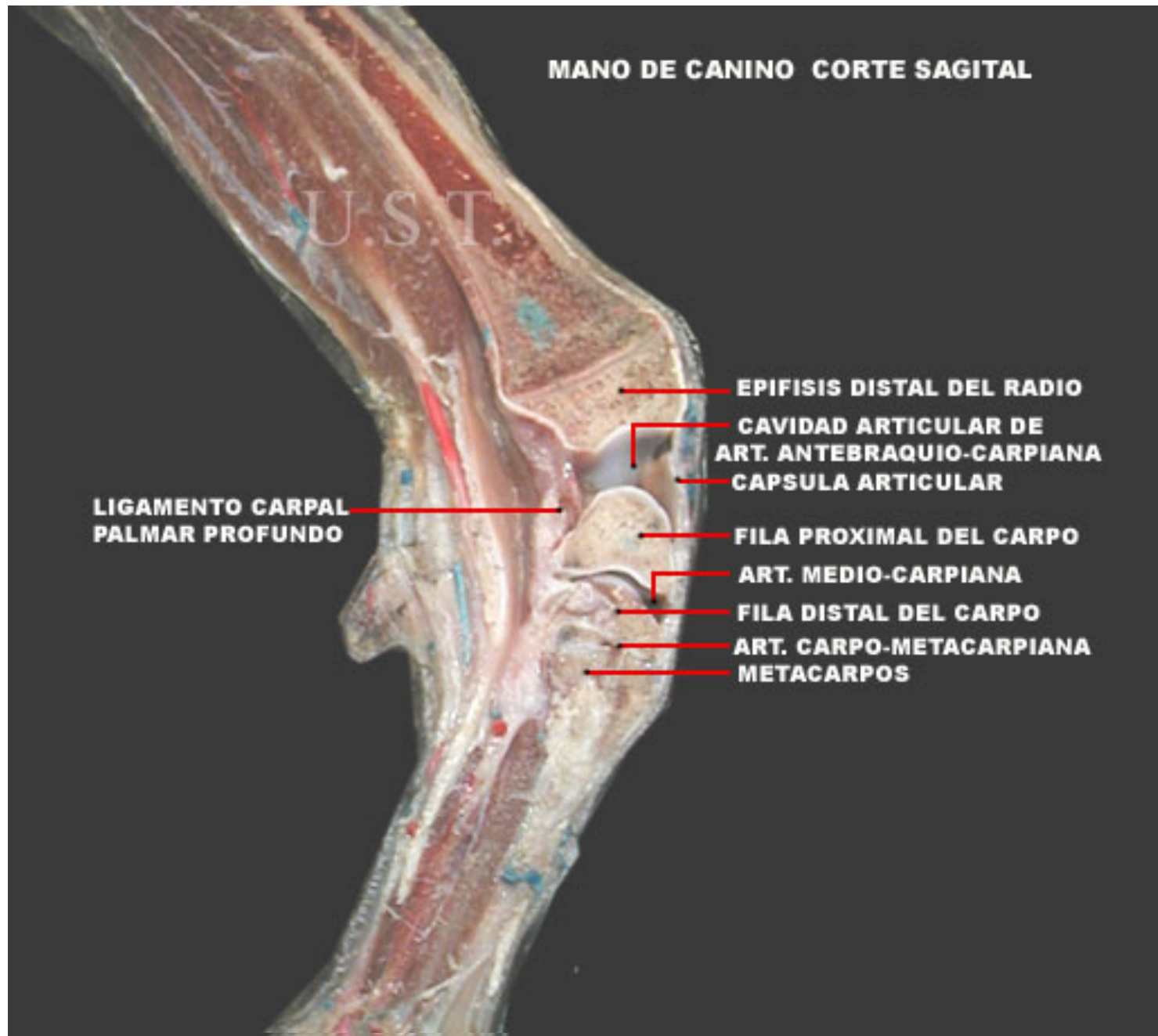




Articulación Codo



MANO DE CANINO CORTE SAGITAL



**LIGAMENTO CARPAL
PALMAR PROFUNDO**

EPIFISIS DISTAL DEL RADIO

**CAVIDAD ARTICULAR DE
ART. ANTEBRAQUIO-CARPIANA**

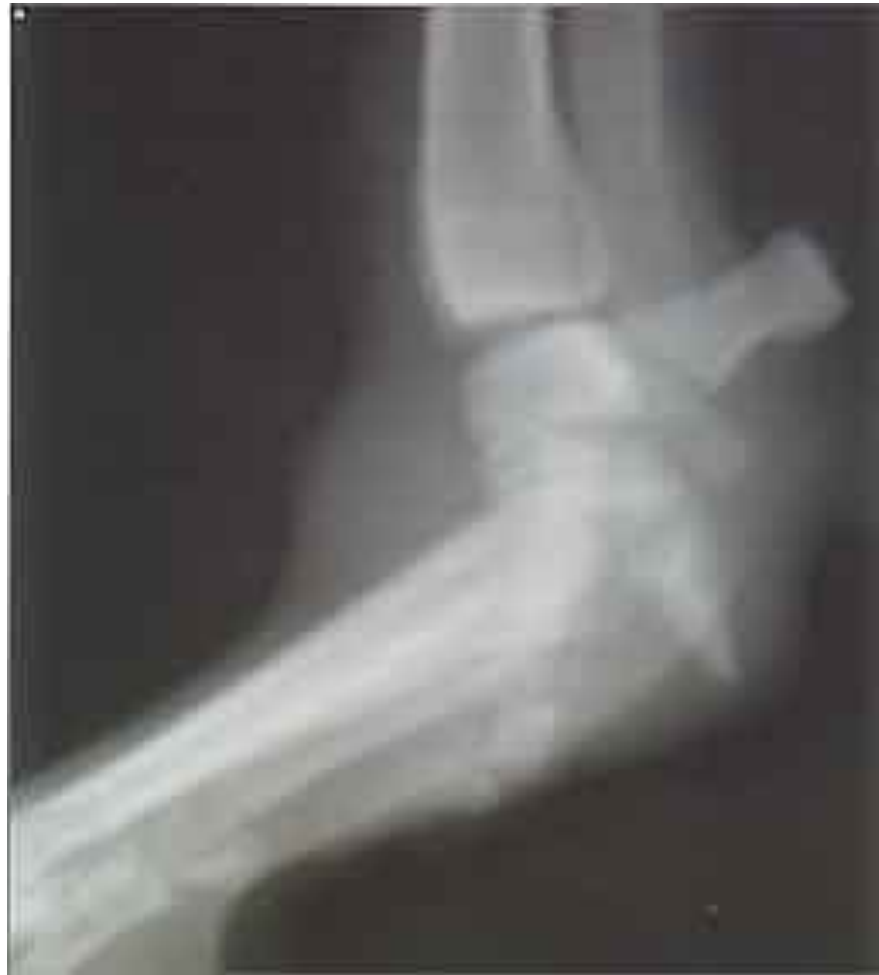CAPSULA ARTICULAR

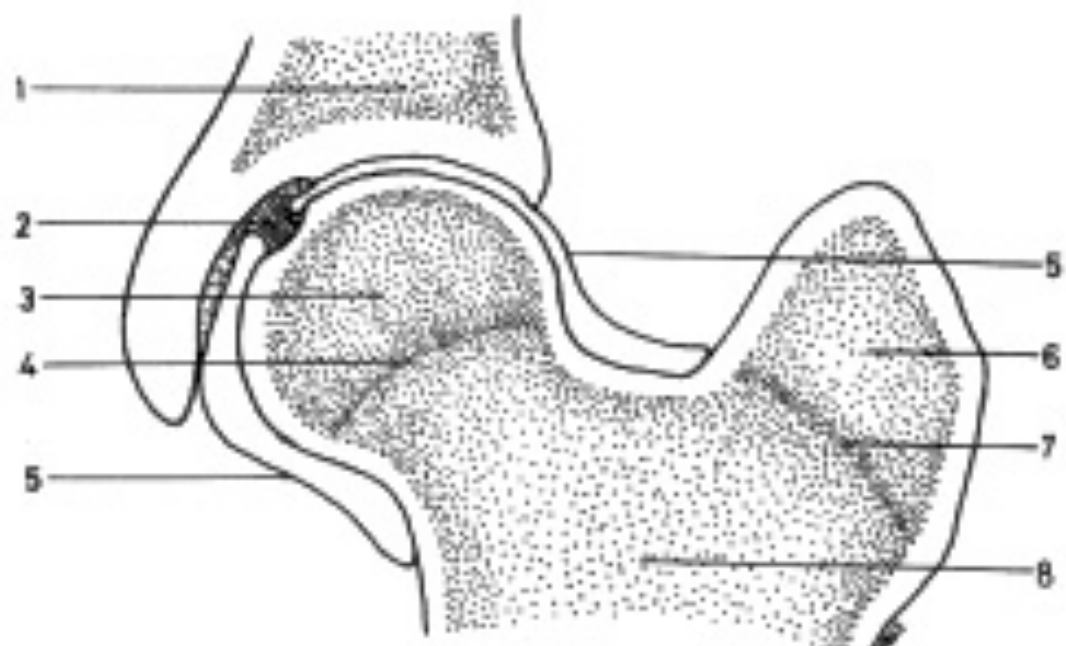
FILA PROXIMAL DEL CARPO

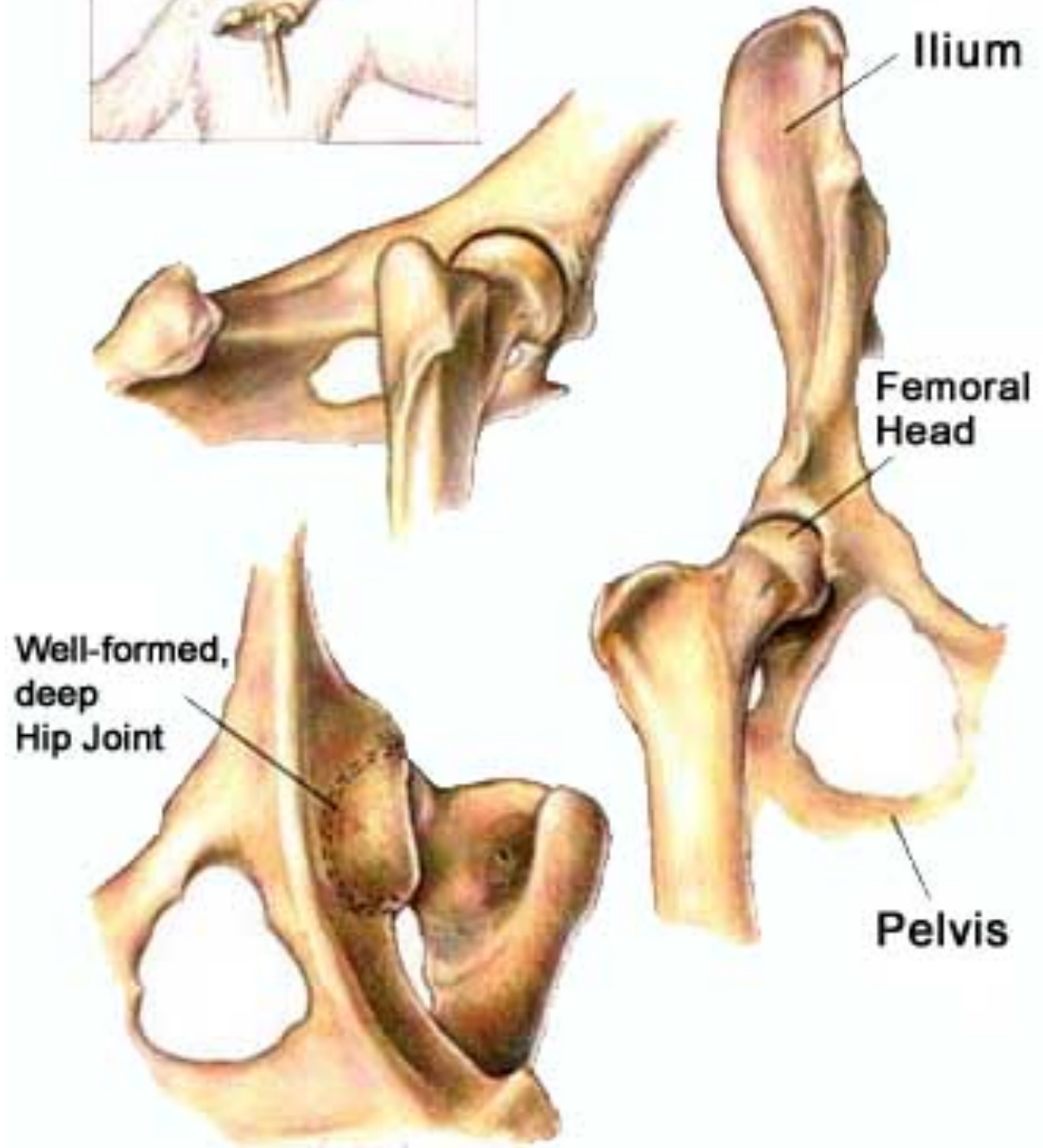
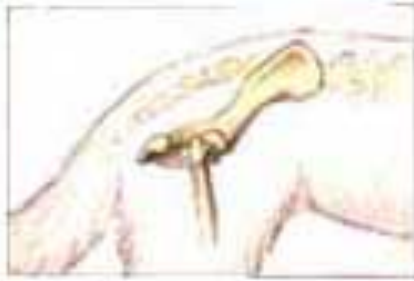ART. MEDIO-CARPIANA

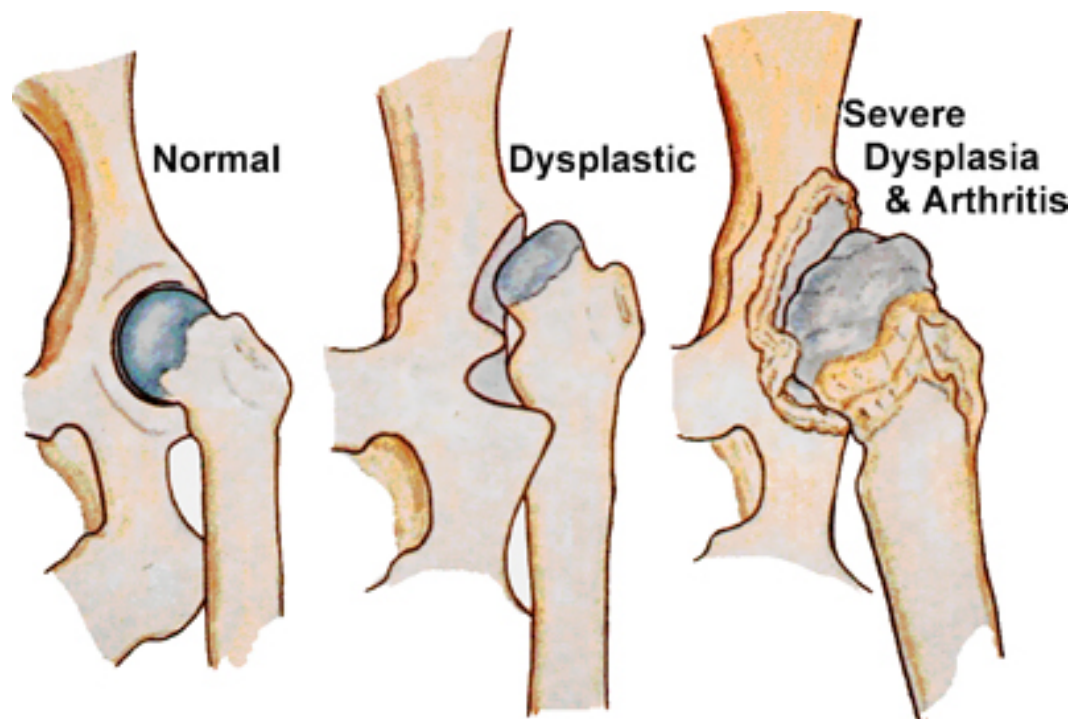
FILA DISTAL DEL CARPO

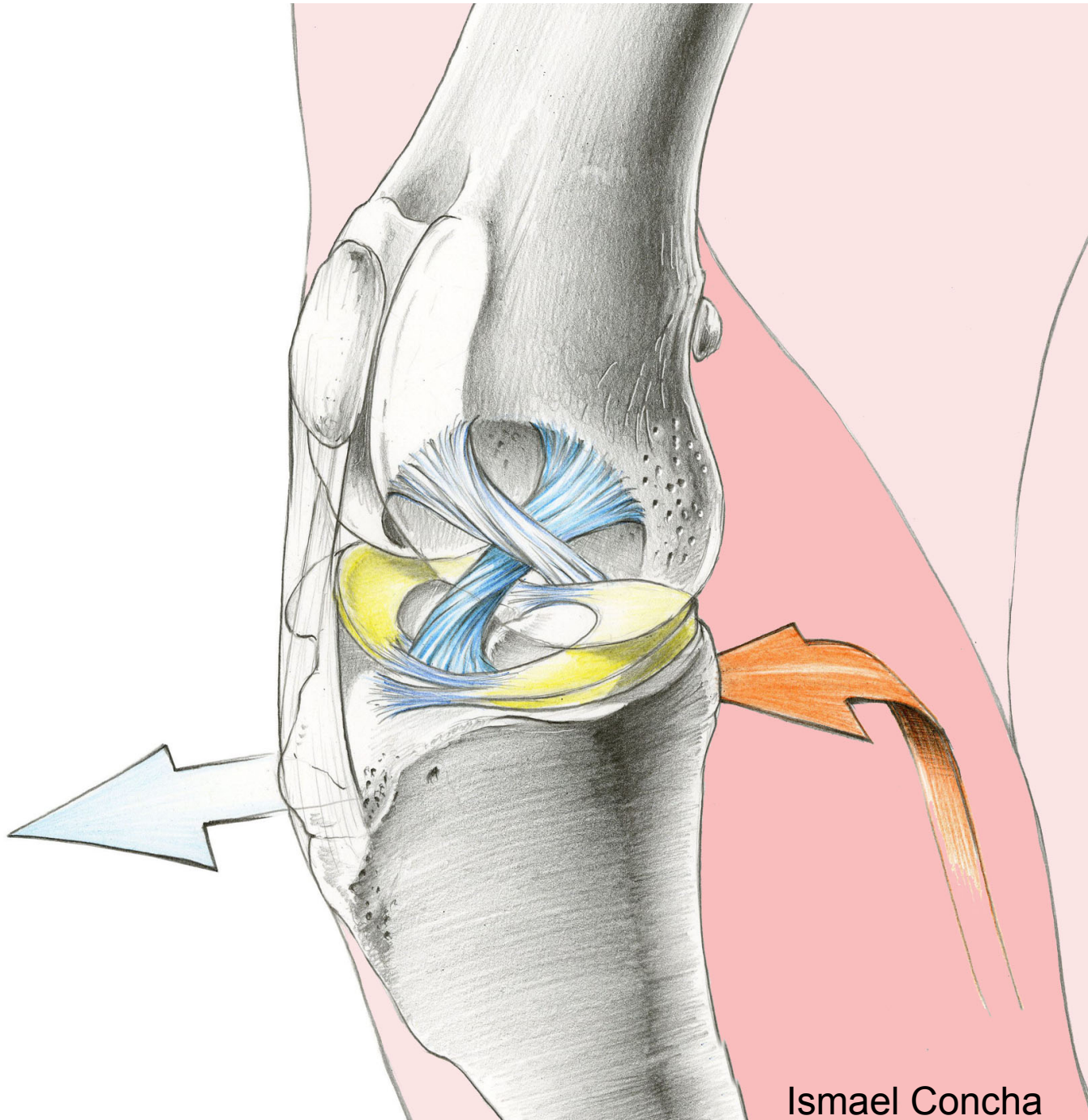
**ART. CARPO-METACARPIANA
METACARPOS**



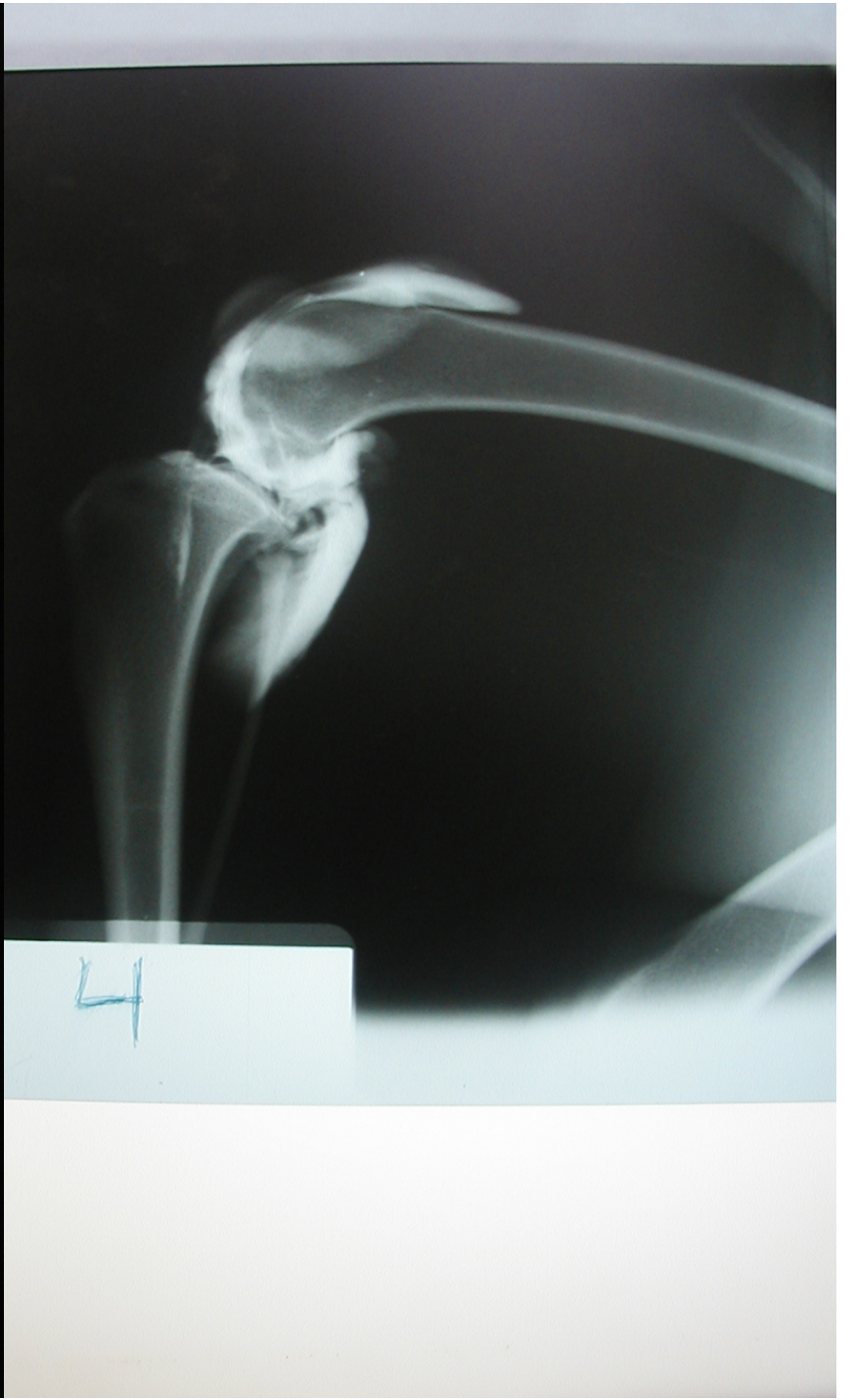
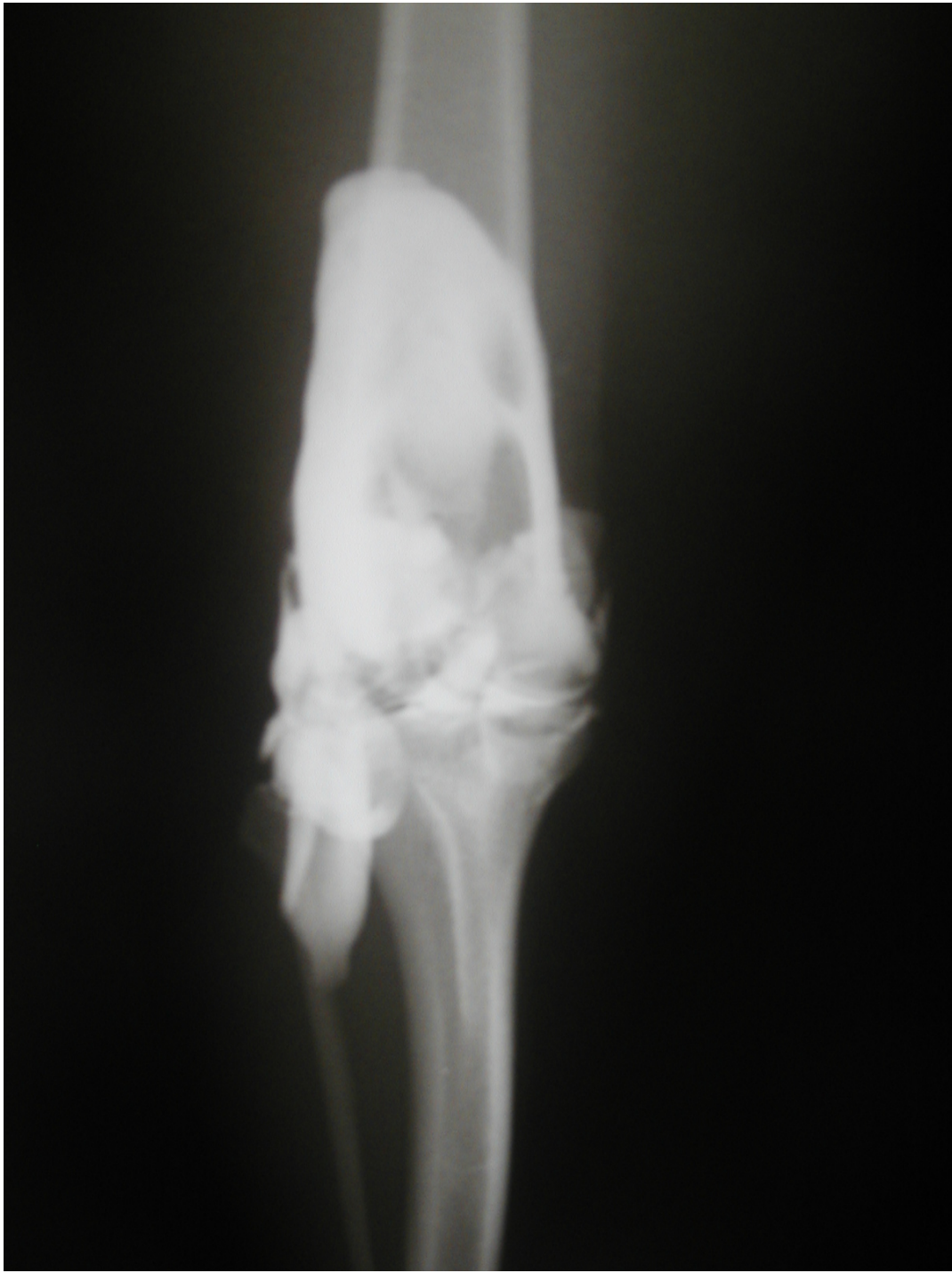
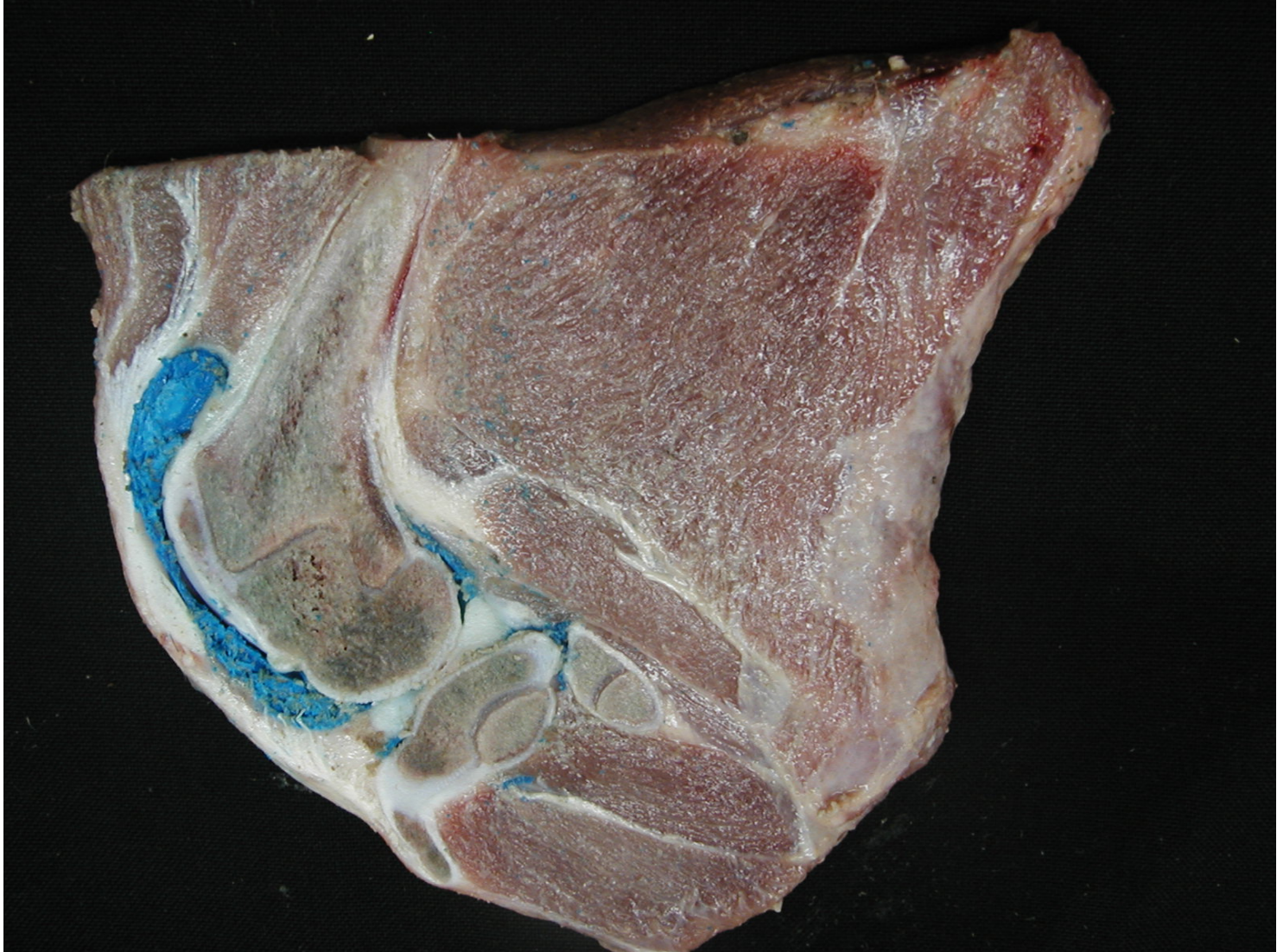




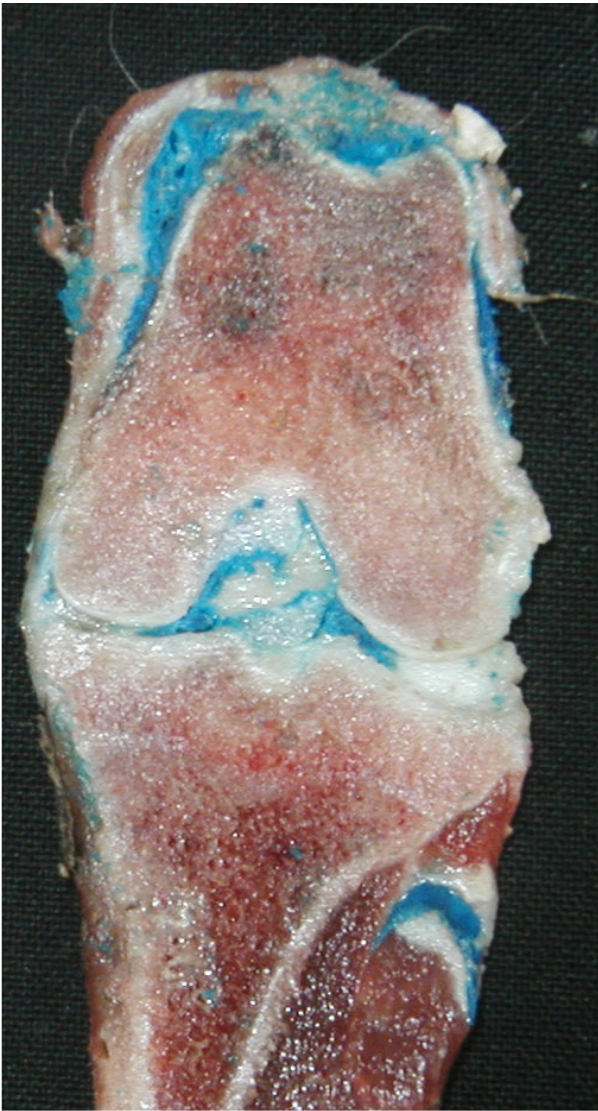

Ismael Concha







**ARTICULACION INTERFALANGICA DISTAL
VISTA DORSAL**

U.S.T.

**TENDONES
EXTENSORES
DIGITALES**

**LIGAMENTOS
ELASTICOS**

